

Treatment of extensive furcation defect associated with accessory foramina: case report

Bernardo Almeida **AGUIAR**¹

Luciana Maria Arcanjo **FROTA**¹

Suyane Maria **LUNA-CRUZ**¹

Maria Gerusa Brito **ARAGÃO**²

Bruno Carvalho de **VASCONCELOS**¹

DOI: <https://doi.org/10.14436/2358-2545.7.3.022-026.oar>

ABSTRACT

Introduction: Understanding of pulp cavity variations is necessary to guarantee success of endodontic treatment, which makes relevant the recognition of accessory canals in furcation areas (FC). **Objective:** The aim of this study was to report a clinical case of a mandibular first molar associated with extensive bone loss in furcation area with the presence of an accessory canal.

Case report: Patient's complaint was the appearance of "bubbles surrounding the tooth." Clinic examination revealed fistula associated with pulp necrosis of tooth #36. There were no signs of periodontal disease. Radiographic evaluation demonstrated wide bone rarefaction in both furcation and periapical areas. After careful cavity access, a radiograph was taken, by means of which it was diagnosed that the FC connected the pulp chamber and

the furcation area. Root canals were localized, followed by chemo-mechanical preparation. Periodic changes of calcium hydroxide were performed after 240 days, satisfactory repair was observed. After 270 days, the canals were filled and their openings as well as the FC sealed with MTA. The 360-day follow-up revealed absence of unwanted clinic signals and bone neoformation in the furcation area. **Conclusion:** The recognition of FC is essential in Endodontics, and so it is to identify its relationship with furcation lesions in teeth without clinical signs of periodontal disease. In these cases, proper decontamination of root canals system is capable of solving endo-periodontal problems, restoring patient's health and avoiding unnecessary treatment.

Keywords: Root canal preparation. Endodontics. Furcation defects. Pulp cavity.

How to cite: Aguiar BA, Frota LMA, Luna-Cruz SM, Aragão MGB, Vasconcelos BC. Treatment of extensive furcation defect associated with accessory foramina: case report. *Dental Press Endod.* 2017 Sept-Dec;7(3):22-6. DOI: <https://doi.org/10.14436/2358-2545.7.3.022-026.oar>

¹Universidade Federal do Ceará, Programa de Pós-graduação em Odontologia (Fortaleza/CE, Brazil).

²Universidade Estadual de Campinas, Faculdade de Odontologia de Piracicaba, Programa de Pós-graduação em Odontologia (Piracicaba/SP, Brazil).

» The authors report no commercial, proprietary or financial interest in the products or companies described in this article.

» Patients displayed in this article previously approved the use of their facial and intraoral photographs.

Submitted: October 31, 2016. Revised and accepted: January 17, 2017

Contact address: Bruno Carvalho de Vasconcelos
Av. Stanislau Frota s/n, CEP: 62.000-000, Sobral/CE, Brasil
E-mail: bcv@ufc.br

Introduction

In a long term basis, pulp tissue health is maintained by preventing oral microorganisms from invading the pulp via caries or accessory canals, among which are apical foramen, lateral or secondary canals, and accessory canals in bi- or trifurcation areas of molars. The latter are defined as small canals with blood vessels arising from the pulp chamber, extending into the inter-radicular dentin to finally reach the periodontal ligament in the furcation area. Furcation canals (FC) connect pulp tissue and periodontal tissue.¹

For endodontic treatment success, infection pathways leading to the root canal system must be eliminated. Complete understanding of pulp cavity morphology and its surrounding structures is essential to determine a cause-and-effect relationship, particularly in the presence of bone rarefaction lesions in the furcation area of teeth with apparently healthy periodontium. In these cases, the presence of an accessory canal in furcation area (FC) might be hypothesized, since it can allow toxic products to reach the furcation area of multirroot teeth, thus spreading contamination, causing or exacerbating endo-periodontal lesions.^{2,3,4}

A few authors have observed periodontal lesions might cause degeneration of pulp tissues, and pulp tissue lesions might affect the severity of periodontal lesions in the affected tooth.² This affirmation can be clinically proved, since after effective endodontic treatment, tissues that support the teeth exhibit satisfactory healing, regression of lesions, and tissue repair.⁵ Thus, an accurate diagnosis is paramount, as it diminishes the risk of recommending inadequate clinical procedures, such as extraction, for the treatment of multirroot teeth presenting extensive furcation lesion.

The aim of this study was to report a clinical case of extensive bone loss in the furcation area of left mandibular first molar (#36) induced by pulp necrosis relative to the presence of a FC. The periodontium was healthy and treatment proposed was extraction.

Case report

A 26-year-old healthy female patient sought clinical assistance in a Primary Healthcare Center reporting the appearance of “bubbles surrounding the tooth.” Based on the results of clinical and radiographic examinations (Figs 1A and B), the patient was referred to extraction of tooth #36. Nevertheless, even after a more detailed clinical examination, it was not possible to determine a cause-and-effect relationship, since periodontal tissues were healthy (Fig 1C). Thus, the patient was referred to an endodontist who performed a cold sensitivity test and diagnosed pulp necrosis. Subsequently, it was decided to perform endodontic treatment, starting by accessing the cavity, removing the pulp chamber ceiling, and exposing the opening of pulp canals (Fig 2A). However, odontometry revealed a connection between pulp chamber and furcation, which made the professional re-examine the pulp chamber floor. During this second examination, the presence of a FC was detected near the opening of mesial canals (Figs 2B and C).

Knowing the causative factor of infection, chemo-mechanical preparation of root canals was performed using a 2.5% sodium hypochlorite solution associated with manual instrumentation with K-files (Dentsply-Maillefer, Ballaigues, Switzerland). Calcium hydroxide was employed as intracanal dressing, and glass ionomer cement used as provisional restorative material. The dressing was changed four times within a period of 240 days, after which satisfactory bone repair was observed (Fig 3A).

After 270 days, without clinical signs of infection, but evident reduction of the rarefaction area, root canal filling was carried out using gutta-percha and resin-based root canal sealer with calcium hydroxide in its composition (Sealer 26, Dentsply-Brazil, Teresópolis, Brazil). Filling was lowered 2.0 mm below the opening of mesial root canals, which allowed the region to be sealed with MTA (MTA-Angelus, Angelus Odontológica, Londrina, Brazil). Subsequently, the tooth was restored with glass ionomer cement and a light-cured dental composite (Fig 3B). The 360-day follow-up revealed absence of clinical signs and symptoms, as well as improvement in bone regeneration in furcation area (Fig 3C).

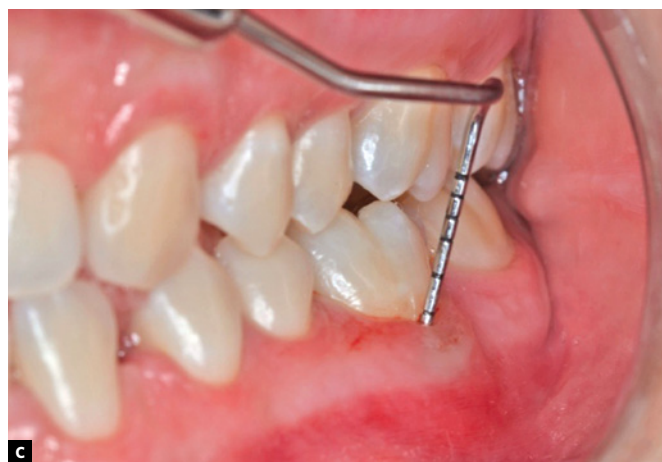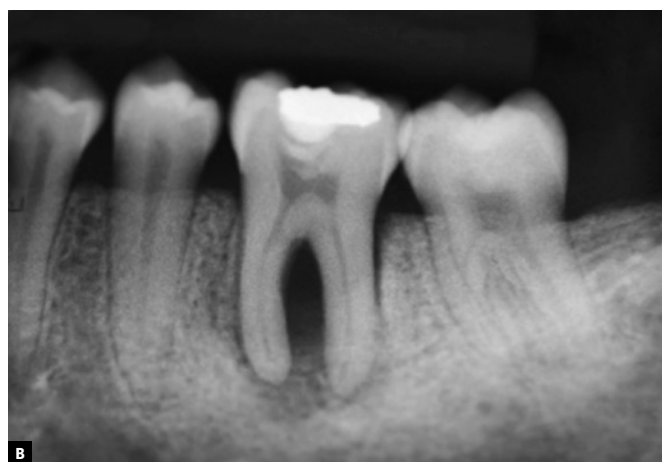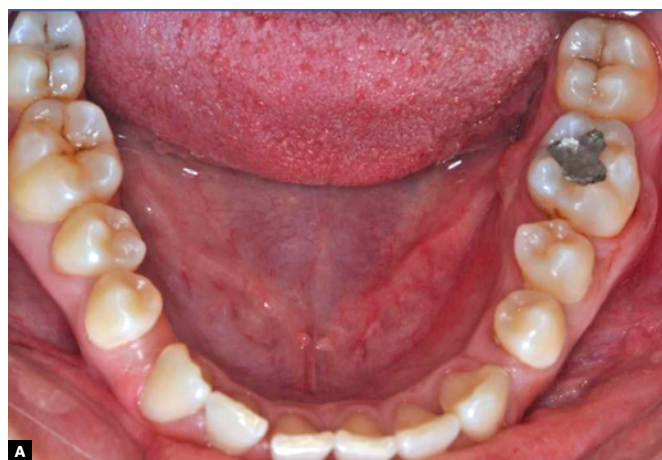


Figure 1. **A)** Tooth presenting fistula. **B)** Periapical radiograph exhibiting extensive bone loss in furcation area. **C)** Clinical examination evincing periodontal health.

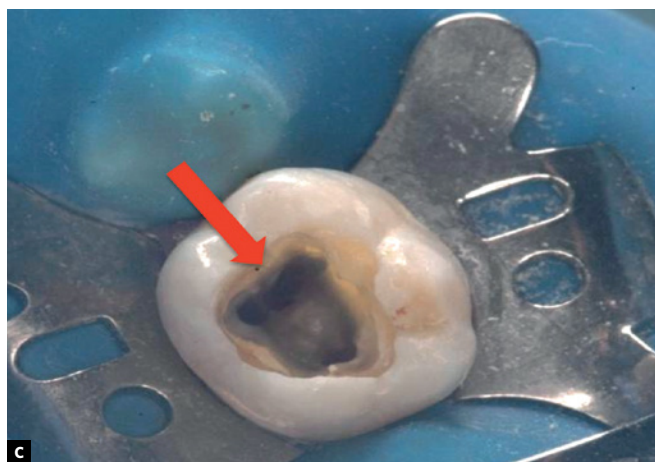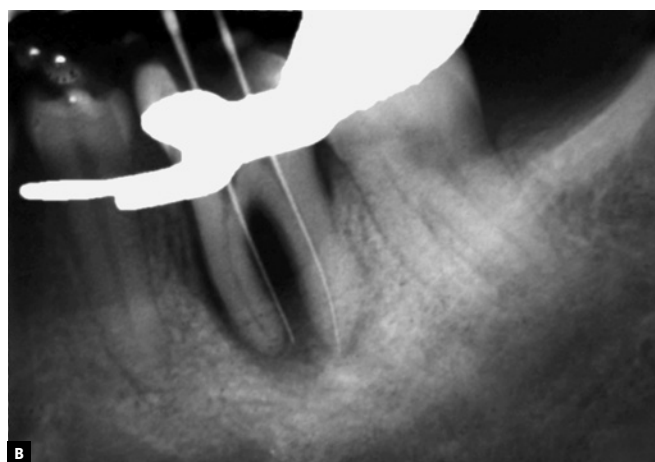

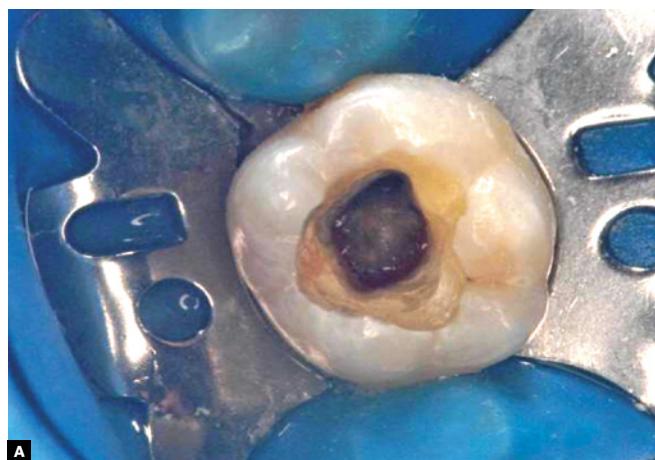
Figure 2. **A)** Removal of pulp chamber roof and exposure of root canal openings. **B)** Periapical radiograph evincing the presence of communication between pulp chamber and furcation area. **C)** Image presenting accessory canal in furcation area near mesial canal openings.

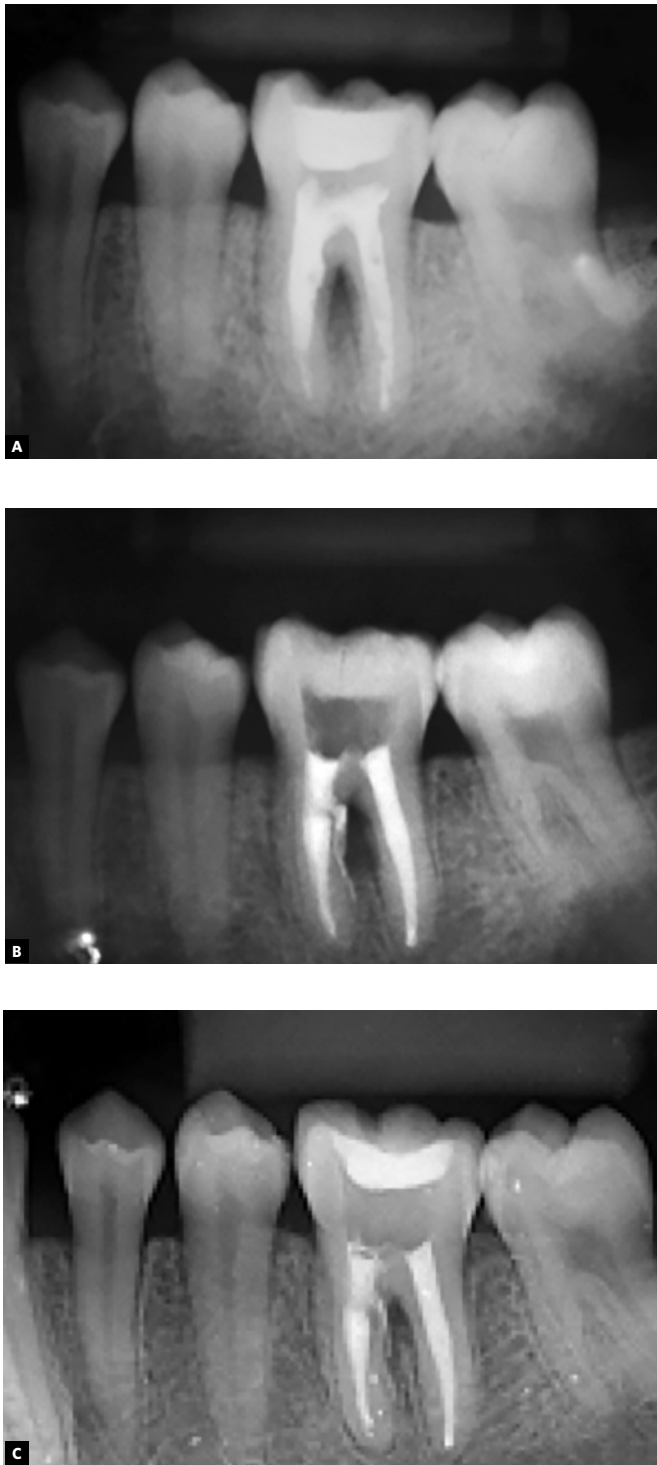


Figure 3. **A)** Periapical radiograph with calcium hydroxide dressing after 240 days. **B)** Periapical radiograph showing root canal filling in the 270-day appointment. **C)** 360-day follow-up.

Discussion

In this case report, the proportion of bone loss in the furcation area influenced the recommendation of extraction. However, absence of clinical signs determining periodontal disease was key to seek other possible diagnoses and treatment. Detailed examination of pulp chamber allowed identification of an accessory canal in furcation area of tooth #36 which was also associated with pulp necrosis, wide bone loss in the furcation area, and absence of periodontal disease. Bone loss in the furcation area might be caused by endodontic microorganisms that percolate from accessory canals, or it might be related to the permeability of the pulp chamber floor.⁶

Knowing the anatomical traits of root canals must be a requirement for clinicians performing endodontic treatment, since variations such as furcation canals are difficult to diagnose using only conventional radiographic techniques.⁷ The case reported in this study demonstrated it was not possible to detect the furcation canal using radiographs only. Diagnosis was achieved only after exploration of the pulp chamber and odontometry.

Although the apical foramen is considered the main via of communication between pulp and periodontium,⁸ accessory and lateral canals may be present throughout the extension of roots. They occur in 30 to 40% of teeth, mainly in the apical third. They can also be found in around 74% of furcation areas of molars, being considered a via of communication between pulp and periodontium.^{8,9}

The trajectory of accessory canals from the pulp chamber to the furcation area is a reliable explanation for the fact that such pathways might be the cause of infection transmission from the pulp to the periodontium.² The presence of furcation canals is an anatomically normal finding, and it is well known that such canals do not represent any risk when the pulp is healthy and vital.¹⁰⁻¹²

Despite extension of bone loss, and with exclusion of periodontal disease diagnosis, it was decided

to perform the calcium hydroxide dressing changes intending to improve decontamination reached by chemo-mechanical preparation of root canals, as well as to collaborate with repair of furcation because of bioactivity of calcium hydroxide.^{13,14,15} The use of calcium hydroxide is recommended as intra-canal dressing due to the fact that it promotes reinsertion of periodontal ligament, recovery of alveolar bone, in addition to cement formation. This intra-canal dressing is proved effective against reminescent bacteria that might remain within canals after mechanical instrumentation. It also controls persistent exudation, and reduce the destructive action of osteoclasts responsible for external root resorption.^{13,16,17}

Nevertheless, effective sealing of FC opening was paramount to the maintenance of repair. The MTA-based sealer was chosen due to its biological and bioactive proprieties associated with marginal sealing and mechanical resistance.¹⁸⁻²¹

Conclusion

Knowledge about the presence of a FC and its relationship with furcation lesions in teeth without clinical signs of periodontal disease is extremely important. In these cases, correct decontamination of root canals can solve endo-periodontal infections, even in wide proportions, thus reestablishing patient's health and avoiding unnecessary treatment.

References

- Shambarger S, Johnson D, Versulius-Tantbirojin D, Bowles WR, McClanahan SB. The incidence of furcation region patency in molars before and after simulated periodontal therapy. *Northwest Dent.* 2015 Mar-Apr;94(2):27-32.
- Haznedaroğlu F, Ersev H, Odabaşı H, Yetkin G, Batur B, Aşçı S, et al. Incidence of patent furcal accessory canals in permanent molars of a Turkish population. *Int Endod J.* 2003 Aug;36(8):515-9.
- Dammaschke T, Witt M, Ott K, Schäfer E. Scanning electron microscopic investigation of incidence, location, and size of accessory foramina in primary and permanent molars. *Quintessence Int.* 2004 Oct;35(9):699-705.
- Vertucci FJ, Anthony RL. A scanning electron microscopic investigation of accessory foramina in the furcation and pulp chamber floor of molar teeth. *Oral Surg Oral Med Oral Pathol.* 1986 Sept;62(3):319-26.
- Meng HX. Periodontic-endodontic lesions. *Ann Periodontol.* 1999 Dez;4(1):84-90.
- Rubach WC, Mitchell DF. Periodontal diseases, accessory canals and pulp pathosis. *J Periodontol.* 1996 Jan-Feb;36:34-8.
- Pineda F, Kuttler Y. Mesiodistal and buccolingual roentgenographic investigation of 7275 root canals. *Oral Surg Oral Med Oral Pathol.* 1972 Jan;33(1):101-10.
- Rotstein I, Simon JH. Diagnosis, prognosis and decision-making in treatment of combined periodontal-endodontic lesions", *Periodontol* 2000. 2004;34:165-203.
- Lin S, Tillinger G, Zuckerman O. Endodontic-periodontic bifurcation lesions: a novel treatment option. *J Contemp Dent Pract.* 2008 May 1;9(4):107-14.
- Vertucci FJ. Root canal morphology and its relationship to endodontic procedures. *Endod Top.* 2005 Nov;10(1):3-29.
- Niemann RW, Dickinson GL, Jackson CR, Wearden S, Skidmore AE. Dye ingress in molars: furcation to chamber floor. *J Endod* 1993 June;19(6):293-6.
- Czarnecki RT, Schilder H. A histologic evaluation of the human pulp in teeth with varying degrees of periodontal disease. *J Endod.* 1979 Aug;5(8):242-53.
- Estrela C, Sydney GB, Bammann LL, Felipe Júnior O. Mechanism of action of calcium and hydroxyl ions of calcium hydroxide on tissue and bacteria. *Braz Dent J.* 1995;6(2):85-90.
- Vineeta N, Gupta S, Chandra A. Retrieval of calcium hydroxide intracanal medicament with Chitosan from root canals: an in vitro CBCT volumetric analysis. *J Conserv Dent.* 2014 Sept;17(5):454-7.
- Camargo EJ, Vivan RR, Bramante CM, Duarte MAH, Graeff MSZ, Silva PAA, et al. The influence of calcium hydroxide on adaptation and root canal penetration in teeth filled with methacrylate-based resin sealer. *Dental Press Endod.* 2015 Sept-Dec;5(3):21-7.
- Marion JJC, Manhães FC, Bortoluzzi TC, Duque TM. The influence of calcium hydroxide paste change on repairing of extensive periapical lesions: cases report. *Dental Press Endod.* 2013 Jan-Apr;3(1):61-7.
- Nery MJ, Gomes-Filho JE, Holland R, Souza V, Bernabé PFE, Otoboni Filho JA, et al. Evaluation of calcium hydroxide dressing for short term prevention of coronal leakage. *Dental Press Endod.* 2011 Oct-Dec;1(3):27-33.
- Bogen G, Kuttler S. Mineral trioxide aggregate obturation: a review and case series. *J Endod.* 2009 June;35(6):777-90.
- Wahengbam B, Wahengbam P, Tikku AP. A simplified technique of orthograde MTA obturation on the elected canals of posterior teeth: two case reports. *J Conserv Dent.* 2014 Jan-Feb;17(1):80-4.
- Andrade FB, Alcalde MP, Guimarães BM, Beleze Neto P, Arias MPC, Bramante CM, et al. Effects of various additives on antimicrobial, physical and chemical properties of mineral trioxide aggregate (MTA). *Dental Press Endod.* 2015 Jan-Apr;5(1):19-29.
- Santos FS. Clinical application of Portland cement. *Dental Press Endod.* 2012 Jan-Mar;2(1):59-64.