

Use of calcium hydroxide paste associate with 2% chlorhexidine gel and zinc oxide as dressing: case report

Sérgio Henrique Staut **BRUNINI**¹

Débora Cristina **GOTTERT**²

Caroline da Rocha **COLDEBELLA**²

DOI: <https://doi.org/10.14436/2358-2545.7.3.070-077.oar>

ABSTRACT

Introduction: Intracanal dressings should be used because shaping and cleaning alone do not eliminate microorganisms adhered to the canal walls. In specific cases, treatment may have to be conducted over several visits, which may have an adverse effect because success depends on patient's cooperation to return to the office several times. Thus, medication combinations are important, as they remain in the root canal for long periods of time. The activity of each substance is then preserved, which can be achieved by combining calcium hydroxide, 2% chlorhexidine gel and zinc oxide. **Case report:** Removal of root canal filling material from tooth #11 was carried

out using Gates-Glidden burs and K-files combined with gutta-percha solvent. After that, intracanal dressing containing calcium hydroxide was applied and left in place for 20 days, with no symptom remission. A paste composed of calcium hydroxide, 2% chlorhexidine gel and zinc oxide at a 2:1:2 ratio was then applied, kept in the canal for five months and not renewed before lesion regression was confirmed radiographically. **Conclusion:** The combination of calcium hydroxide, 2% chlorhexidine gel and zinc oxide effectively controlled infection without renewal of intracanal dressing.

Keywords: Root canal treatment. Periapical abscess. Calcium hydroxide. Chlorhexidine.

How to cite: Brunini SHS, Gottert DC, Coldebella CR. Use of calcium hydroxide paste associate with 2% chlorhexidine gel and zinc oxide as dressing: case report. Dental Press Endod. 2017 Sept-Dec;7(3):70-7.

DOI: <https://doi.org/10.14436/2358-2545.7.3.070-077.oar>

Submitted: December 05, 2016. Revised and accepted: March 14, 2017

» The authors report no commercial, proprietary or financial interest in the products or companies described in this article.

» Patients displayed in this article previously approved the use of their facial and intraoral photographs.

¹Unipar, Supervised Internship in Multidisciplinary Clinic (Umuarama/PR, Brazil).

²Unipar, School of Dentistry (Umuarama/PR, Brazil).

Contact address: Sérgio Henrique Staut Brunini
Rua Bartira, 2745, Jardim São Marcos
CEP: 87.501-440 – Umuarama/PR
E-mail: brunini@unipar.br

Introduction

Endodontic treatment is based on prevention, diagnosis and treatment of diseases that affect the tooth pulp and periapical region.¹ Bacteria found in root canals may be eliminated due to mechanical action of endodontic instruments or the use of irrigating solutions. However, studies in the literature confirm that cleaning and shaping is not enough for full elimination of microorganisms adhered to the root canal walls, which indicates the need to use intracanal dressing as a complementary resource immediately after cleaning and shaping and before filling, extending endodontic treatment along several visits.²

In specific cases —such as treatment of root canals with root resorption, incomplete root formation, persistent fistula or lesions refractory to endodontic treatment—, treatment has to be conducted during several visits, which may have an adverse effect and decrease treatment compliance, because it depends on greater patient's cooperation to return to the dental office several times.

Regular patient return to the dental office to renew intracanal dressing is difficult to achieve. Therefore, medication combinations should be developed, so as to allow them to remain in the root canal for longer periods of time while preserving the action of each substance used. This may avoid the need for recurrent patient's visits, and dentists may have a new alternative for endodontic treatment.

Calcium hydroxide, one of the substances most often used as intracanal dressing, is chosen for a large number of cases, such as pulp necrosis, apexification and root resorption, because of its properties. Success of calcium hydroxide is primarily assigned to its dissociation into calcium and hydroxyl ions. To enhance its effect, different substances are combined with it, in which case they should be studied to analyze whether those substances may affect the properties of calcium hydroxide paste.³

One of those substances is 2% chlorhexidine, which has yielded positive results because of its broad antimicrobial effect, absorption to dentinal tissue and satisfactory tissue tolerance. The purpose of its addition is to increase the antimicrobial properties of calcium hydroxide while preserving the biological and mechanical characteristics of the latter as physical barrier.⁴ Their combination does not affect

the capacity of calcium hydroxide to dissociate into calcium and hydroxyl ions and, therefore, does not interfere with its capacity to elevate pH.

Zinc oxide, a solid compound obtained from zinc melting and reaction with oxygen, has been used in combinations with 2% chlorhexidine gel and calcium hydroxide as intracanal dressing. This use yields favorable results in maintaining pH and antimicrobial activity, thus proving effective in apexification.²

In vitro studies on the combination of calcium hydroxide, chlorhexidine and zinc oxide showed its capacity of diffusion in root dentin and inhibition of bacterial growth. These studies suggest that the three substances combined may remain for a longer period in the root canal without being renewed while preserving its antimicrobial effect by diffusion to dentinal tubules.²

Thus, the present study describes a clinical case of endodontic retreatment with the use of calcium hydroxide paste combined with 2% chlorhexidine gel and zinc oxide kept in the root canal without renewal for an extended period of time. It also discusses a treatment alternative for clinical cases that require intracanal dressing to remain in the canal for a long time.

Case report

A 53-year-old female patient was referred to a dental clinic for endodontic retreatment of tooth #11 because of a fistula in the buccal vestibule. Clinical examination revealed two well-adapted composite resin restorations in the mesial and distal angles, in addition to lingual restoration that sealed the opening of endodontic access cavity. Responses to vertical percussion and buccal vestibule palpation were moderately positive. Radiographs showed a small radiolucent area in the root apex of tooth #11 and root canal filling without any detectable voids in condensation that, according to the patient, had been performed 10 years before. The diagnosis was chronic periapical abscess, and retreatment was recommended (Fig 1). Before any procedure was performed, treatment plan for this clinical case was approved by the Institutional Review Board for Research with Human Subjects of *Universidade Paranaense* (main campus, Umuarama, Brazil) under protocol #60431416.9.0000.0109.

During the first visit, restoration sealer previously inserted into the endodontic access cavity and root canal filling material were removed with the aid of a #3 Gates-Glidden bur in both cervical and middle thirds. To remove filling material from the apical third, a #30 K-file was used together with eucalyptol, with the latter being neutralized by irrigation with 5 mL 92% ethanol. Subsequently, the root canal was copiously irrigated with 2.5% sodium hypochlorite solution, and an electronic apex locator (Root ZX, J Morita, Japan) was used to determine total tooth length by inserting a file until the locator indicated the tip had reached the root apex. Working length was determined at 1 mm short from total tooth length, as indicated by the electronic apex locator, for further biomechanical preparation. Cleaning and shaping were performed using K-files coupled to a contra-angle handpiece (TEP-10 – NSK) performing 45° right-to-left movements, from a file used for filling material removal to a #50 file. Calcium hydroxide paste (Calen) was placed in the canal, and access opening was sealed using provisional filling material (Coltosol).

Ten days later, the patient reported exacerbation of clinical symptoms: pain increased, particularly during mastication, and there was discreet volume increase in the area near the fistula, which was rather reddish. After removal of provisional filling material and once irrigation of the root canal had been carried out with saline solution to remove calcium hydroxide paste (used as intracanal dressing), paper cones were used to dry the root canal, showing that exudate was draining out of the apical foramen. Fresh calcium hydroxide paste was placed into the canal, and the cavity opening was sealed with provisional filling material. Amoxicillin and paracetamol were prescribed for pain relief.

After other ten days, the patient presented with mild reduction in sensitivity and slight reduction in edema. The fistula remained clinically evident. Radiographs showed an increase in the radiolucent area of the root apex of tooth #11, which confirmed the condition was deteriorating (Fig 2A). After removing the provisional filling material and intracanal dressing, a paste containing calcium hydroxide (P.A.), 2% chlorhexidine gel and zinc oxide was prepared at a 2:1:2 ratio and putty-consistent, and subsequently placed into root canal at full extension with the aid

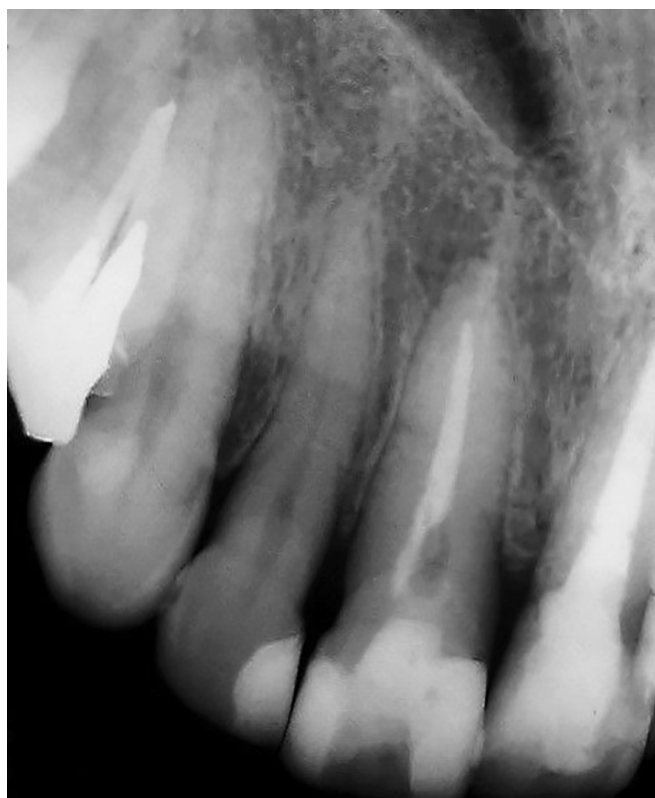


Figure 1. Initial radiograph of tooth #11.

of an endodontic probe. A cotton ball and provisional glass ionomer cement were used to close it. Another radiograph taken to check whether the root canal had been completely filled revealed filling material overflow through apical foramen (Fig 2B).

The patient was seen again 15 days later for follow-up. She reported that on the fifth day after intracanal dressing had been applied, she detected some whitish material overflowing out of the fistula, which remained open, all of which was confirmed by clinical examination. Radiographs revealed material overflow through apical foramen, which suggested that the whitish material oozing out of the fistula, according to the patient, could be the filling material that was extruded (Fig 3). Despite the clinical condition described above, no other type of intervention was considered, and the original follow-up plan was kept.

Intracanal dressing was kept in the root canal for six months, and the patient had only two follow-up visits during this time. The first was scheduled 25 days after the visit described above. Clinical exam-

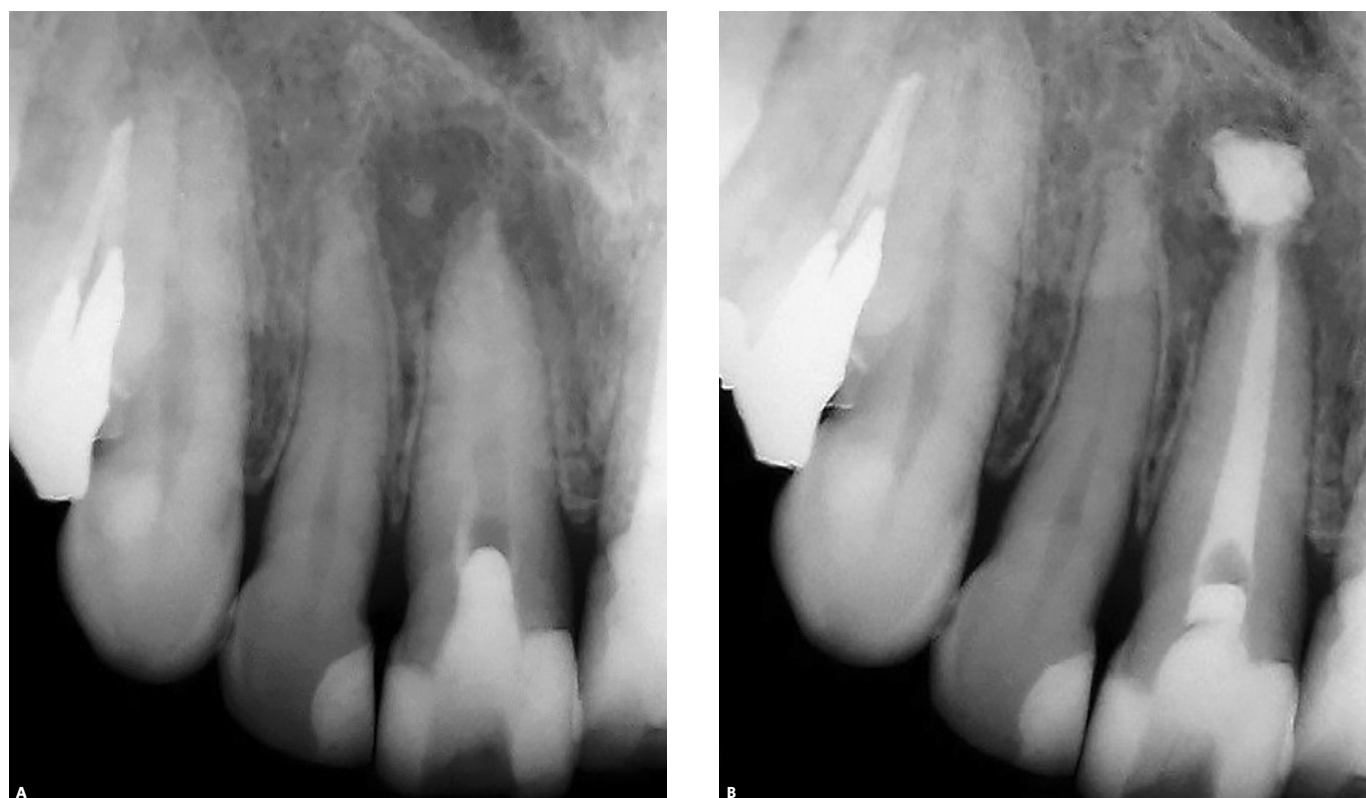


Figure 2. A) Radiograph shows increase of radiolucent area. B) Root canal filled with calcium hydroxide, 2% chlorhexidine gel and zinc oxide paste.

ination revealed the fistula in the buccal vestibule remained visible, but the patient did not report any type of symptom. New radiographs showed intracanal dressing remained in the root canal, and that there were no signs of resorption (Fig 4A). Intracanal dressing was only renewed in the following visit, which was 60 days later, at a total of four months from beginning to the end of treatment. At this time, the fistula was no longer visible, and radiograph showed the paste used as intracanal dressing remained intact, with no signs of dissolution (Fig 4B). The decision not to replace it was kept.

Sixty days later, radiographs revealed the periapical lesion had started to regress. The root canal was then filled with an M accessory gutta-percha cone (Diadent) and calcium hydroxide endodontic sealer (Sealapex – Sybron) by means of Tagger hybrid technique (Fig 5A). A post-operative control radiograph taken two years and six months after treatment completion showed the radiolucent area close to the apex of tooth #11 had disappeared completely (Fig 5B).

Discussion

Endodontic practice has established that bacteria have a decisive role in the success or failure of root canal treatment. Elimination of canal infection, usually achieved by shaping and cleaning with irrigation solutions, is one of the major objectives of endodontic therapy. However, infection elimination is a complex task to be achieved using only chemicals and mechanical instrumentation. Therefore, the use of an antibacterial substance should remain an important complement in the elimination of bacteria during endodontic treatment.⁵

Several strategies have been suggested for treatment of teeth after endodontic treatment failure. Management of post-treatment pathologies includes non-surgical retreatment and/or intracanal dressing, apical surgery, or extraction and immediate implant placement. The option chosen in the clinical case reported herein was non-surgical retreatment, the preferred alternative due to being less invasive. Additionally, clinical procedures should be performed

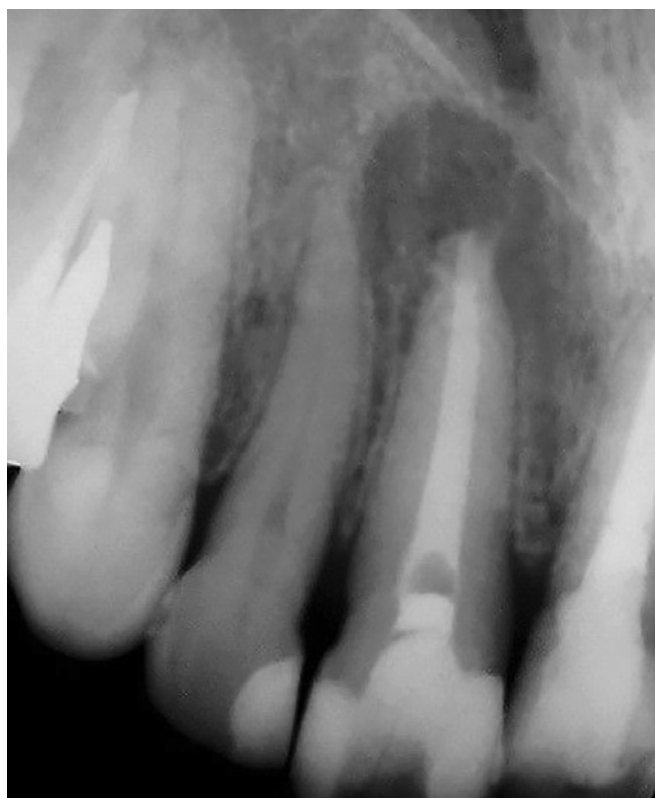

Figure 3. Radiograph shows extruded filling material oozing out of fistula.

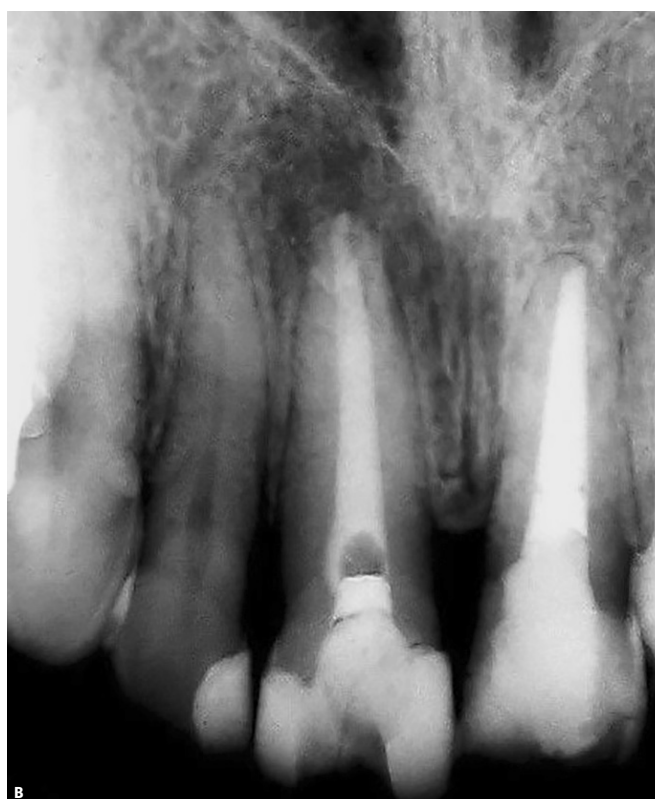
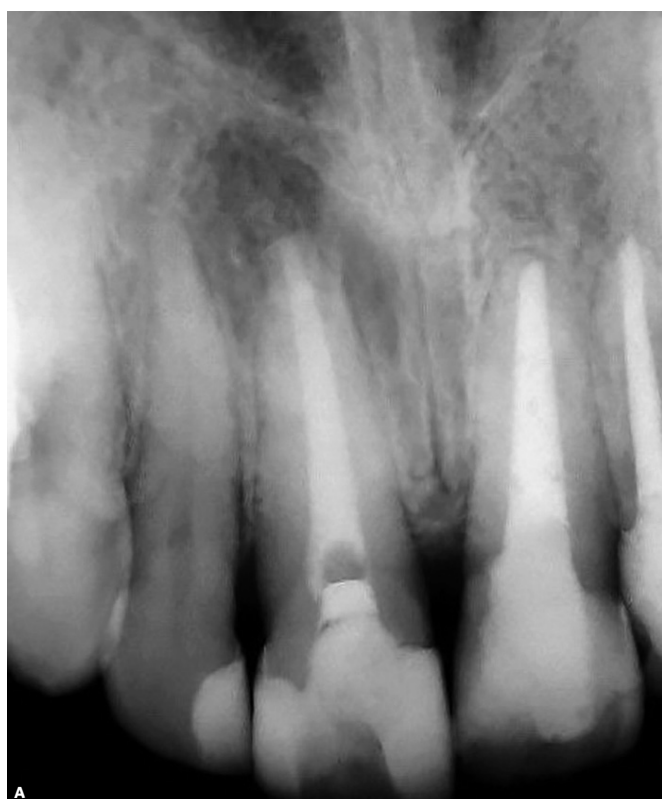
Figure 4. Control radiographs: **A)** 60 days; **B)** 120 days.

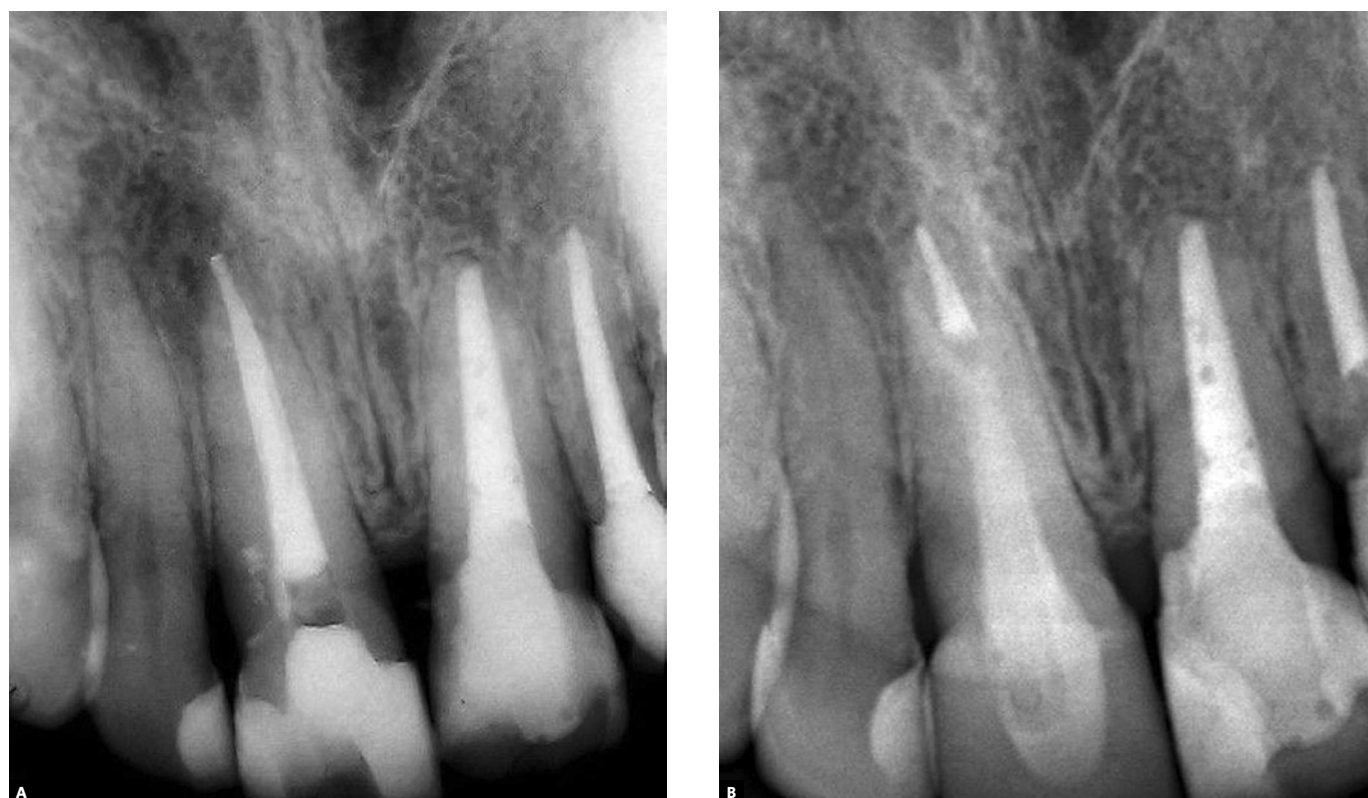

Figure 5. **A)** Final radiograph taken immediately after filling was completed; **B)** Post-operative control radiograph take 2 years and 6 months after treatment was completed.

to remove the original filling material, followed by repeated shaping and adequate infection control and prevention, essential to maximize the success of new treatment. This retreatment should include rigorous asepsis, complete cleaning and shaping using antimicrobial irrigants, application of intracanal dressing and repeated root canal filling, as well as satisfactory crown sealing.⁶

In cases of filling with little condensation of filling material, the use of hand files, such as Hedström files, may successfully remove the material using a grasping and pulling technique. However, when filling is firmly compacted, risks of using purely mechanical methods to remove gutta-percha, such as perforation, fracture or changes in original root curvature, should not be ruled out. In such conditions, filling material removal demands more time and the use of a greater variety of files and techniques, which may provide greater efficiency, speed and practicality in removing gutta-percha. Warmed files, microscopes, ultrasound

and solvents may be used.^{7,8} In the clinical case described herein, a combination of resources was used to remove original filling: Gates-Glidden burs were used for mechanical removal of gutta-percha from the cervical and middle thirds of the root canal, together with the application of eucalyptol to dissolve gutta-percha and hand K-files to remove filling material from the canal completely. Eucalyptol was chosen as solvent as it is a widely used substance in Endodontics, and reports confirm its lower toxicity than that of other substances used for the same purpose.⁹ However, contact with the apical region should be avoided. Eucalyptol is an essential oil obtained from several eucalyptus species, and according to its manufacturer, it is practically insoluble in water, although miscible with ethanol. Therefore, after gutta-percha was dissolved, ethanol was used for irrigation in an attempt to neutralize and eliminate all eucalyptol residues that might have remained in the root canal and might have a residual irritating effect.

The oscillating file system selected for cleaning and shaping has properties that are similar to those of any other automated system when compared to the use of hand files. Its use results in greater comfort, shorter operative time and less operator fatigue than rotary systems. Moreover, its cost is lower, as conventional files can be used.¹⁰ Another reason in this clinical case was the fact that the tooth to be treated had root without curves, which poses fewer difficulties and does not justify the use of rotary systems that demand greater investments in the purchase of systems with limited useful life. The latter should be reserved for more complex cases.

Exacerbation of the clinical condition after the first visit may be assigned to calcium hydroxide deficiency. Although this is a widely used drug in Endodontics, it may not be classified as a universal intracanal dressing because it is not equally efficient against all bacteria found in the root canal. Moreover, its efficacy is associated with diffusion of hydroxyl ions through dentinal tubules and accessory canals in areas where bacteria and their byproducts may remain.^{4,11} The development of this skill demands time, which requires a strategy of periodic calcium hydroxide renewal that should usually occur every thirty days. Therefore, it requires several visits to the dental office, in addition to having inevitable clinical costs and increasing the risk of tooth fracture, thereby reducing patient's willingness to accept treatment.

These disadvantages may be overcome by associating calcium hydroxide with other substances that improve its action while preserving its biological and mechanical characteristics. One of these substances is chlorhexidine.^{4,11}

According to Gomes et al⁴ and Souza Filho et al,¹¹ the combination of these two substances decreases the antimicrobial activity of chlorhexidine, but increases that of calcium hydroxide. Sirén et al¹² found that this association is more effective than calcium hydroxide alone. They reported that the addition of chlorhexidine did not affect the alkalinity of suspension; it may potentially be used for a long time; and toxicity tests showed the association was not more toxic than its components separately.

Zinc oxide, the third substance added to this combination, is a potent inhibitor of the proteolytic activity of metalloproteinases and acts in the degradation of extracellular matrix components during inflammation.²

According to Buck et al,¹³ calcium hydroxide, 2% chlorhexidine gel and zinc oxide should be combined at a 2:1:2 ratio, which results in a provisional filling paste of adequate consistency for clinical placement into the root canal. In addition, it has antimicrobial properties, capacity to maintain an alkaline pH from the moment it is placed in the root canal,¹⁴ better than the one obtained when using chlorhexidine or calcium hydroxide alone,¹¹ can diffuse in dentin rapidly^{2,13} and remain in the canal for long periods of time.¹⁵

In this clinical case, calcium hydroxide, chlorhexidine and zinc oxide paste remained in the root canal without being replaced for about five months. Several studies^{2,13,15,16} found that this paste does not require replacement for up to nine months, which results in a better condition for the patient, fewer visits to the dental office and reduced costs.

When filling the root canal with intracanal dressing, overflow should be avoided because this material does not undergo resorption, which could be confirmed for the time the paste remained in the root canal. In our case, radiographs did not show areas of material dissolution, which is in agreement with findings in the literature suggesting this type of filling is preserved by the presence of zinc oxide, as calcium hydroxide dissociates after a number of months. According to literature, under the conditions described herein, zinc oxide reacts as efficient inert sealing material that prevents contamination of the root canal and provides satisfactory repair in the periapical region.^{13,15,16}

Conclusion

The use of intracanal dressing that may be kept for a longer time in the root canal without periodic replacement to preserve its therapeutic activity favors patient's treatment compliance and avoids early discontinuation, which, therefore, results in a higher rate of treatment conclusion and acceptable success rates.

References

1. Leonardo MR, Leonardo RT. Tratamento de canais radiculares. Avanços tecnológicos de uma Endodontia minimamente invasiva e reparadora. São Paulo: Artes Médicas; 2012.
2. Soares AJ. Análise clínica e radiográfica de dentes traumatizados submetidos a um protocolo de medicação intracanal com a associação hidróxido de cálcio, clorexidina gel 2% e óxido de zinco, sem trocas periódicas [tese]. Piracicaba (SP): Universidade de Campinas; 2007.
3. Quidute IL. Hidróxido de cálcio como medicação intracanal [monografia]. Recife: ABO; 2001.
4. Gomes BP, Vianna ME, Sena NT, Zaia AA, Ferraz CC, Souza Filho FJ. In vitro evaluation of the antimicrobial activity of calcium hydroxide combined with chlorhexidine gel used as intracanal medicament. *Oral Surg Oral Med Oral Pathol Oral Radiol Endod.* 2006 Oct;102(4):544-50.
5. Sjögren U, Figdor D, Spångberg L, Sundqvist G. The antimicrobial effect of calcium hydroxide as a short-term intracanal dressing. *Int Endod J.* 1991 May;24(3):119-25.
6. Endo MS, Ferraz CC, Zaia AA, Almeida JF, Gomes BP. Quantitative and qualitative analysis of microorganisms in root filled teeth with persistent infection: monitoring of the endodontic retreatment. *Eur J Dent.* 2013 July;7(3):302-9.
7. Agnes AG. Retratamento endodôntico: uma revisão de literatura [monografia]. Porto Alegre (RS): Universidade Federal do Rio Grande do Sul; 2009.
8. Oyama KON, Siqueira EL, Santos M. In Vitro study of effect of solvent on root canal retreatment. *Braz Dent J.* 2002;13(3):208-11.
9. Oyama KON, Siqueira EL, Santos M. Ação de diferentes solventes sobre os cones de guta-percha. *ECLER Endod.* 1999;1(3):1-8.
10. Wagner MH, Barletta FB, Reis MS, Mello LL, Ferreira R, Fernandes ALR. NSK Reciprocating handpiece: in vitro comparative analysis of dentinal removal during root canal preparation by different operators. *Braz Dent J.* 2006;17(1):10-4.
11. Souza-Filho FJ, Soares AJ, Vianna ME, Zaia AA, Ferraz CC, Gomes BP. Antimicrobial effect and pH of chlorhexidine gel and calcium hydroxide alone and associated with other materials. *Braz Dent J.* 2008;19(1):28-33.
12. Sirén EK, Haapasalo MP, Waltimo TM, Ørstavik D. In vitro antibacterial effect of calcium hydroxide combined with chlorhexidine or iodine potassium iodide on *Enterococcus faecalis*. *Eur J Oral Sci.* 2004 Aug;112(4):326-31.
13. Buck CLBP, Soares AJ, Buck A, Nagata JY, Zaia AA, Souza Filho FJ. Avaliação de dentes reimplantados submetidos a um novo protocolo terapêutico. *Rev Assoc Paul Cir Dent.* 2013;67(1):22-6.
14. Cunha LFM, Ehlers IFR, Brunini SHS. Comparison of changes in the pH of calcium hydroxide pastes associated with different vehicles. *Dental Press Endod.* 2013;3(3):32-5.
15. Marion JJC, Martellosso LV, Nagata JY, Lima TFR, Soares AJ. Suggesting a new therapeutic protocol for traumatized permanent teeth: case report. *Dental Press Endod.* 2014;4(1):71-7.
16. Soares AJ, Nagata JY, Casarin RCV, Almeida JFA, Gomes BPFA, Zaia AA, et al. Apexification with a new intra-canal medicament: a multidisciplinary case report. *Iran Endod J.* 2012 Summer;7(3):165-70.