

The tooth has pulp vitality and has a periapical lesion: Criteria for diagnosis and treatment

Alberto **CONSOLARO**^{1,2}
 Antônio Cesar Oliveira de **AZEVEDO**²
 Walter João **GENOVESE**³
 Ingrid Araújo **OLIVEIRA**⁴
 Dario Augusto Oliveira **MIRANDA**⁵

DOI: <https://doi.org/10.14436/2358-2545.8.1.008-016.end>

ABSTRACT

Many clinicians get confused when finding a tooth with periapical lesion and unchanged pulp vitality. Several lesions resemble chronic inflammatory periapical lesions when revealed by imaging examination, and teeth remain with pulp vitality. We always have to bear in mind that: 1) teeth with pulp vitality should not be accessed without previous diagnosis of lesions; and endodontic treatment should not be carried out as diagnostic tool or therapeutic test for periapical lesions in teeth with pulp vitality. 2) Carrying out endodontic treatment in teeth with pulp vitality and lesions that resemble periapical periodontitis might extend time dedicated to an appropriate approach and, thus,

considerably worsen lesion prognosis. 3) In teeth with pulp vitality and periapical lesions of undetermined origin, it is key to establish a relationship among clinical, imaging and microscopic specialties, so as to allow for an exchange of experience and knowledge with a view to reaching safe diagnosis and carrying out effective treatment. 4) Lesions mentioned herein should be born in mind or noted down in order to allow for further application in the event of having teeth with periapical lesions and pulp vitality!

Keywords: Periapical periodontitis. Periapical lesions. Pulp vitality.

How to cite: Consolaro A, Azevedo ACO, Genovese WJ, Oliveira IA, Miranda DAO. The tooth has pulp vitality and has a periapical lesion: Criteria for diagnosis and treatment. *Dental Press Endod.* 2018 Jan-Apr;8(1):8-16. DOI: <https://doi.org/10.14436/2358-2545.8.1.008-016.end>

» The authors report no commercial, proprietary or financial interest in the products or companies described in this article.

¹ Universidade de São Paulo, Faculdade de Odontologia de Bauru (Bauru/SP, Brazil).

² Universidade de São Paulo, Faculdade de Odontologia de Ribeirão Preto, Programa de Pós-graduação em Odontopediatria (Ribeirão Preto/SP, Brazil).

³ Universidade Estadual de Feira de Santana, Curso de Odontologia (Feira de Santana/BA, Brazil).

⁴ Universidade Cruzeiro do Sul, Curso de Odontologia (São Paulo/SP, Brazil).

⁵ Doutora em Estomatologia, Universidade de São Paulo, Faculdade de Odontologia de Bauru (Bauru/SP, Brazil).

Submitted: February 16, 2018. Revised and accepted: February 19, 2018

Contact address: Alberto Consolaro
 E-mail: consolaro@uol.com.br

Lesions that resemble inflammatory periapical periodontitis in teeth with pulp vitality

Accessing a tooth crown with pulp vitality and exposing the live pulp in order to extract it while expecting this will solve the problem of periapical lesion with root canal filling is a mistake. It does not add either to diagnosis or to treatment!

Conditions most often leading to the aforementioned situation are as follows:

1. Periapical cemental dysplasia: it is the first hypothesis when it comes to a lesion that resembles periapical lesion in anteroinferior teeth with pulp vitality (Fig 1). In patients from eastern countries, it is found in mandibular premolars and canines.

A definite diagnosis of periapical cemental dysplasia is achieved by a combination of clinical and imaging data; without biopsy, since the condition is characterized as classic. Clinical and imaging examination-based diagnosis is necessarily assured not only by the clinician's vast clinical experience, but also by interaction between clinician and the imaging examination expert. For cases addressed by less experienced clinicians or clinicians with no training in diagnosing intraosseous lesions, it is suggested that they exchange information and experience with other colleagues.

Periapical cemental dysplasia does not require treatment, but imaging as well as clinical follow-up once a year, to say the least, or whenever the patient is available. It is of unknown etiology, although there must be ethnic and genetic factors involved. This is because the condition predominantly affects dark-skin individuals, especially women in their 40s.

Periapical cemental dysplasia, as lesion or disease, is not a benign or malignant neoplasm, but rather a disorder of bone tissue remodeling and formation at the site where it occurs. The latter is nearly exclusively determined as the periapex of anteroinferior teeth, from canine to canine. In the field of developmental disorders, the term "dysplasia" means a change in cell differentiation that results in mal-formed tissue.

Periapical cemental dysplasia does not become malignant nor undergo transformation into more severe diseases. In some patients, the condition might be part of florid cemento-osseous dysplasia. The latter is a similar condition extending throughout the

mandible to the maxilla. Every periapical cemental dysplasia patient should have his/her jaws thoroughly examined, so as the potential presence of similar lesions at other sites is rejected.

Whenever periapical cemental dysplasia affects several teeth with pulp vitality at the same time, diagnosis is achieved with ease (Fig 1). However, in a few cases, the condition begins by affecting one or two teeth. Should that be the case, a thorough study must be carried out, since at its initial stages the condition resembles chronic periapical lesion, particularly when revealed by imaging examination.²

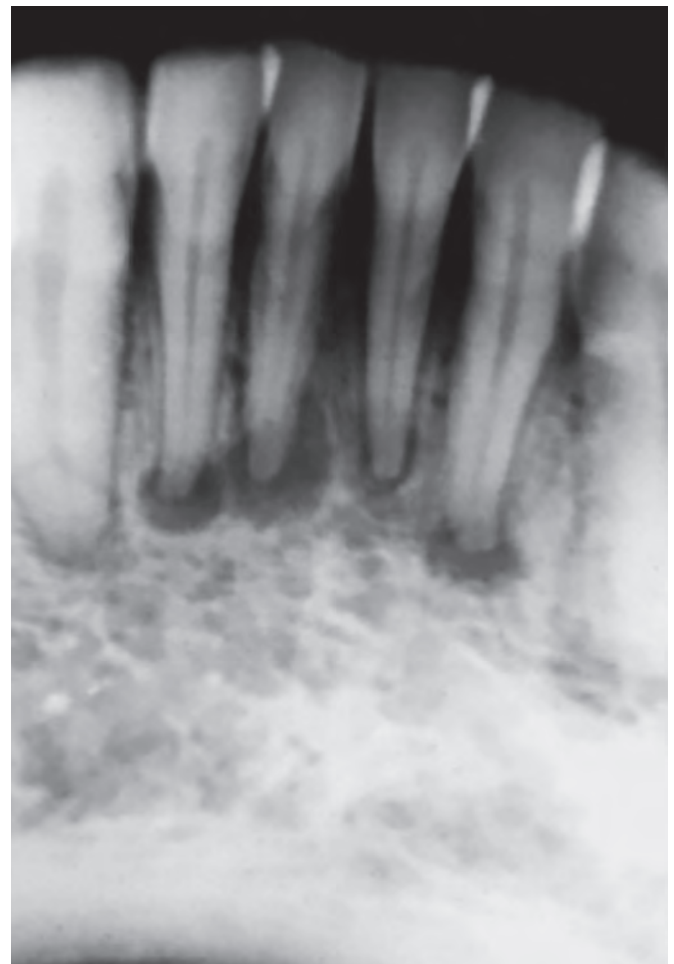


Figure 1. Periapical cemental dysplasia at an early stage. Note it is completely radiolucent.

2. Benign cementoblastoma: it is the first hypothesis when it comes to a lesion that resembles periapical lesion and it is found in mandibular molars, especially first molars (Fig 2). However, it can be found, although rarely, in maxillary molars or deciduous teeth.

Similarly to any other benign neoplasm, benign cementoblastoma growth occurs without any sign, in a slow and asymptomatic manner. It begins at mandibular first molar periapex in more than 80% of cases. Once it has been established, with diameter approximately ranging from 0.5 to 1cm, half of cases may be associated with symptoms such as pain and/or discomfort. As it occurs with nearly all odontogenic tumors, benign cementoblastoma is preferably found in adolescents and young adults with age ranging from 8 to 44 years old.¹

Initially, periapical bone is slowly and gradually replaced by neoplastic tissue of fibroblast, cementoblast, and osteoblast polyhedron-shaped cells that are disorderly arranged. This forms a neoplastic bulk well-defined by a fibrous capsule. At this early stage, imaging examination revealing the minor lesion resembles a radiolucent chronic periapical lesion (Fig 2) of which cells produce dissociated irregular tra-

beculae of bone and cemental tissue that is disorganized and full of clasts on the surface.

Lesion growth leads to the emergence of irregular radiopaque sites. Initially, the latter are dotted, but further merge and form slightly larger radiopaque bulks until they become an irregular radiopaque bulk splashed by radiolucent points (Fig 2). The lesion is surrounded by a well-established and even radiolucent halo that corresponds to the fibrous capsule. At later stages, cortical bone might expand at the site.

From the beginning, the lesion merges with the root that undergoes resorption, as undergone by the periapical bone, and is slowly replaced by irregular neoplastic tissue. Thus, imaging examination does not distinguish the limits between root and lesion, and does not make it clear whether the fibrous capsule formed as an even radiolucent halo remains with the lateral periodontal space.

Endodontic treatment does not produce any beneficial effects on benign cementoblastoma. The latter must be surgically removed by traditional means. Patients only suffer relapse when lesion fragments are left at site. Prognosis is satisfactory. Benign cementoblastoma is not transformed into and does not

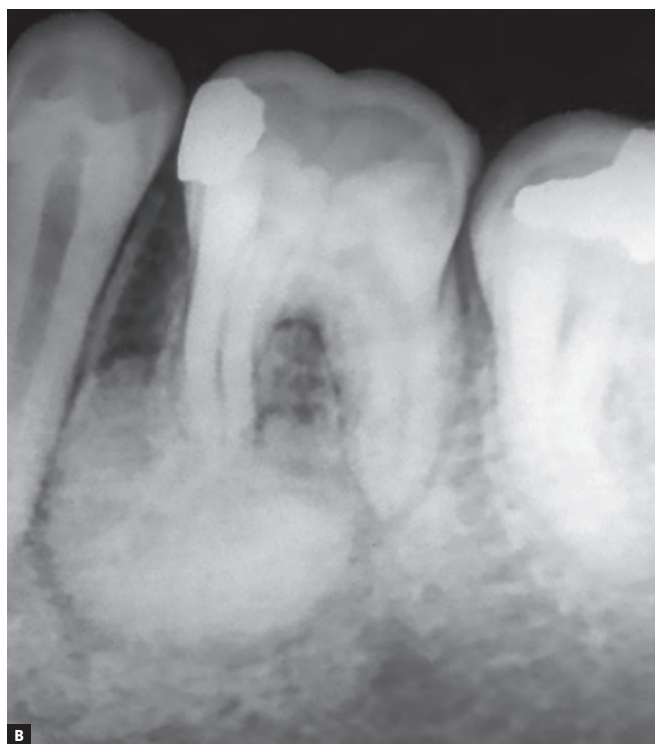
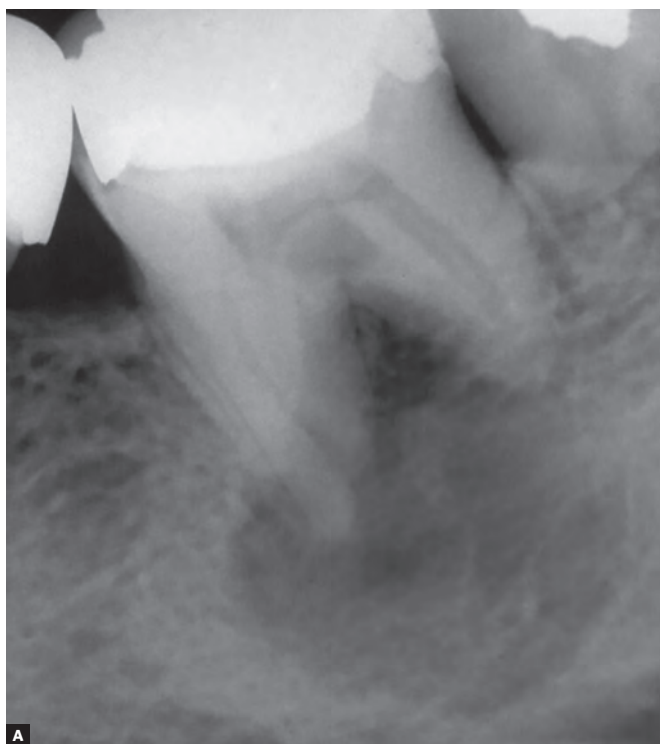

Figure 2. Benign cementoblastoma: **A**, at an early stage; **B**, at a final stage.

cause other lesions, whether benign or malignant. In the majority of cases, the affected tooth is removed along with the lesion. In minor cases, in which only one root is affected, the tooth can be preserved by removing only the root that had merged with the lesion.

3. Nasopalatine cyst: it is the first hypothesis when the lesion that resembles periapical lesion is found in maxillary central incisors (Fig 3). In cases involving apical periodontal cysts found in maxillary central incisors with pulp vitality, one should first speculate about nasopalatine cyst (Fig 3).

The latter emerges from inside the incisive canal as a result of nasopalatine canal remnants in the form of clusters of epithelial cells. It is a developmental cyst of which causal factor is unknown. Furthermore, it is the non-odontogenic cyst most often found in the jaws, an intraosseous lesion that is relatively common in stomatological practice.

Its growth is achieved sideways and symmetrically. Radiographic examination reveals, due to anterior nasal spine overlap, a heart-shaped image in the anterior maxillary midline (Fig 3). Such growth occurring sideways may cause some confusion over periapical radio-

graph, leading one to believe it is an apical periodontal cyst in maxillary central incisor(s) which remain(s) vital when a nasopalatine cyst is present.

In cases of nasopalatine cyst, maxillary central incisors do not undergo resorption, but might have roots displaced, with diverging long axis and converging crowns, which gradually move along the midline and slowly result in crowding.

Maxillary central incisors will present with pulp vitality in cases of nasopalatine cyst. In the event of patient's complaint, in general, the latter results from crown movement and the feeling of some salty taste which is noticed to come from behind maxillary central incisors during tongue sucking. Such a taste is a consequence of secretion or cystic matter found in periodontal space.

Nasopalatine cyst treatment is surgical, and prognosis is rather satisfactory, with no relapse or development into any other type of lesion. In the vast majority of cases, it does not require endodontic intervention on maxillary central incisors with pulp vitality. In a few cases, due to trans-surgical technical reasons, the pulp neurovascular bundle might be affected. Should that be the case, endodontic treatment will be required at the time of surgery or soon after it.

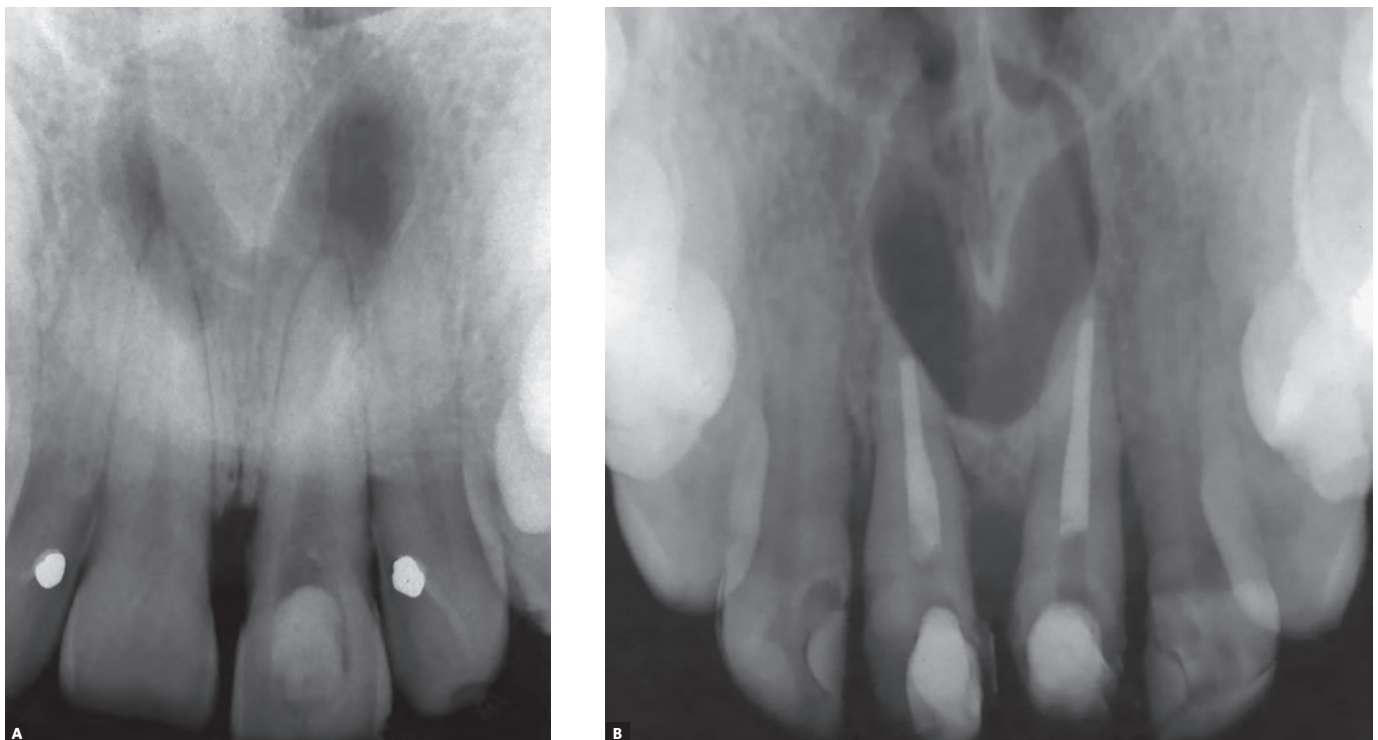


Figure 3. Nasopalatine cysts. Inadequate endodontic approaches carried out as a therapeutic attempt.

4. Simple bone cyst: it is the first hypothesis when it comes to a lesion that resembles periapical lesion in mandibular premolars (Fig 4). However, it might be found at the height of mandibular incisors or molars, as the mandible is the most affected, despite the lesion also being found in other parts of the body.

Simple bone cyst is a bone cavity lacking epithelial lining and having bare walls or walls covered by a thin layer of loose connective tissue. Inside the cystic cavity, there is air and sometimes it is possible to find a small amount of straw-colored fluid filling up to 10% of space. Microscopic examination of extracted fluid often reveals the presence of peripheral blood components. This is due to the needle going through surrounding tissues and, as a result, collecting such components inside them.

The presence of air and well-defined diagnostic imaging may lead to definite diagnosis. At this clinical point, a valid treatment alternative is to fill the cavity with patient's peripheral venous blood, so as to allow for clot formation. The latter is paramount for bone repair.

Simple bone cyst imaging examinations are typical of this type of lesion, with characteristics such as a well-determined and continuous line surrounding the cyst and setting the limits with normal bone (Fig 4). This cystic line perfectly surrounds tooth roots without interrupting the lamina dura while keeping periodontal spaces and root structures unchanged and without tooth resorption. Teeth are not displaced or moved by the presence of the cyst, and present with pulp vitality.

Simple bone cyst is asymptomatic and does not cause cortical bone to become convex, even when its largest axis is a few centimeters long. A fragile mandible might lead to pathological fractures, even with normal masticatory function. Cyst growth is slow and unperceivable by the patient.

Definite diagnosis can be achieved by imaging examination and puncture revealing the presence of air. In addition to injecting peripheral blood into the cavity, another treatment option is to open up the enucleation of the cyst and perform curettage of its walls with a view to filling the cavity with blood and leading to clot formation. This is key to bone neoformation and elimination of lesion.

Before filling the cavity with blood, the clinician should collect sample material for further microscopic analysis via careful curettage of cystic bone walls. After repeated attempts have been made, material collected by recurrent curettage will be minimal. The report will, therefore, describe the presence of inflammation-free loose connective tissue and normal bone medullary tissue. Should a probable diagnosis of simple bone cyst not be included in surgical data, the pathologist usually arrives at a descriptive diagnosis of normal bone and medullary tissue. On the other hand, should probable diagnosis be given, the report might present a diagnosis of "lesion consistent with simple bone cyst."

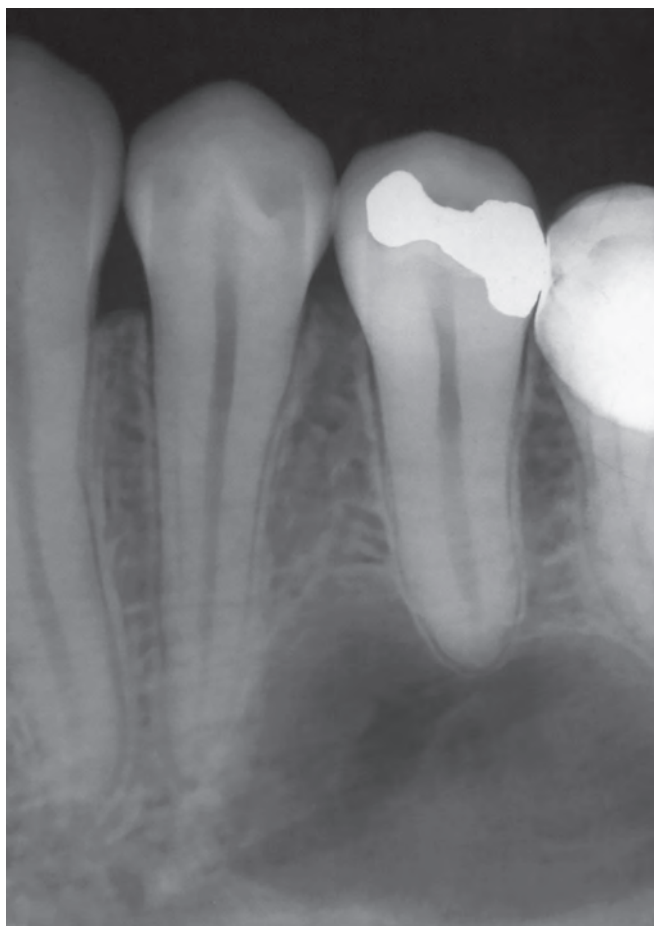


Figure 4. Simple bone cyst in periapical region of premolars. Note root contour without loss of lamina dura.

Simple bone cyst prognosis tends to be quite satisfactory, and the lesion does not become malignant nor undergo transformation into other types of lesion. The lesion is entitled by other names seeking to make an association between the lesion itself and its probable causes, for instance: traumatic bone cyst, hemorrhagic bone cyst, solitary bone cyst, among others.

Simple bone cyst has unknown cause. However, it has been suggested that it results from trauma and hemorrhage at site, with blood clot formation as bone repair matrix. Another hypothesis is intraosseous venous blockage leading to resorption at the area.

In addition to treatment with puncture followed by filling with peripheral venous blood and treatment with curettage with blood clot formation, another recommended approach is imaging follow-up. Due to being a lesion typical of young patients and rarely found among 40-year-olds and older, it is recommended that a number of cases be solved with no intervention. Nevertheless, having a fragile mandible as a result of lesion is inevitable, and for this reason treatment is recommended.

Teeth affected by simple bone cyst have pulp vitality. Endodontic treatment should not be carried out, as it will provide no contribution to solve the problem. In many cases, patients show up for the appointment with one or more affected teeth previously subjected to endodontic treatment. This reveals mistaken diagnosis and clinical protocol.

5. Odontogenic keratocyst: it is a cyst¹ originating in clusters of epithelial cells also known as dental lamina epithelial rests. They are randomly scattered throughout jaw bones, including periodontal ligament and periapical sites.

Up to 1% of apical periodontal cysts might be odontogenic keratocysts² (Fig 5). Should that be the case, affected teeth present with pulp vitality, but do not have affected roots undergoing resorption (Fig 5). Odontogenic keratocyst is asymptomatic. During growth, it does neither break up nor compresses nerve and vascular bundles entering the pulp.

For a few years, odontogenic keratocyst was mistakenly considered as neoplasm; however, more recent WHO publications¹ have reconsidered the issue, thereby understanding it as odontogenic cyst. During the period, it was also known as keratocystic odontogenic tumor.

Odontogenic keratocyst relapse occurs with a high frequency and although rarely, it might lead ameloblastoma to form in its walls. Even more rarely, it might lead to malignant neoplasm formation, as it is the case of carcinomas. In spite of the aforementioned characteristics, it is possible to claim that odontogenic keratocyst prognosis is satisfactory once it has been completely removed and subjected to yearly follow-ups.

In 5% of patients, odontogenic keratocysts are found as multiple keratocysts and might comprise part of the Syndrome of Multiple Keratocysts also known as Nevoid Basal Cell Carcinoma Syndrome or Gorlin-Goltz Syndrome.¹ In addition to multiple odontogenic keratocysts, the syndrome consists of numerous basal cell carcinomas of the skin and several skeletal anomalies, such as increased diameter of skull, clavicular hypoplasia, acne, bifid rib, and others. The syndrome is caused by deletion of a tumor suppressor gene in chromosome 9.

Definite diagnosis of odontogenic keratocyst must be achieved microscopically. Removal of minor odontogenic keratocyst lesions that resemble chronic periapical lesions should also be considered as excision biopsy.

Odontogenic keratocyst surgical removal might mechanically affect nerve and vascular bundle integrity, as the latter enters the pulp. However, this does not necessarily apply to all cases. For this reason, analysis should be carried out in unprecedented detail, carefully assessing the advantages of performing endodontic treatment before surgery, as it might be rendered unnecessary and pulp vitality be preserved. Should the vascular bundle be injured, endodontic treatment might be performed at the time of surgery or soon after it, without postponing it for too many days, since the tooth might then become darker!

Endodontists are the practitioners who most often perform apical endodontic surgery. Their training in surgery is more than enough to technically certify them to address odontogenic keratocysts. Nevertheless, the aforementioned situation might not always be convenient, whether clinically and/or professionally, for several reasons. Thus, the patient might be referred to an oral and maxillofacial surgeon who will be at his/her disposal if need be, according to this other practitioner.

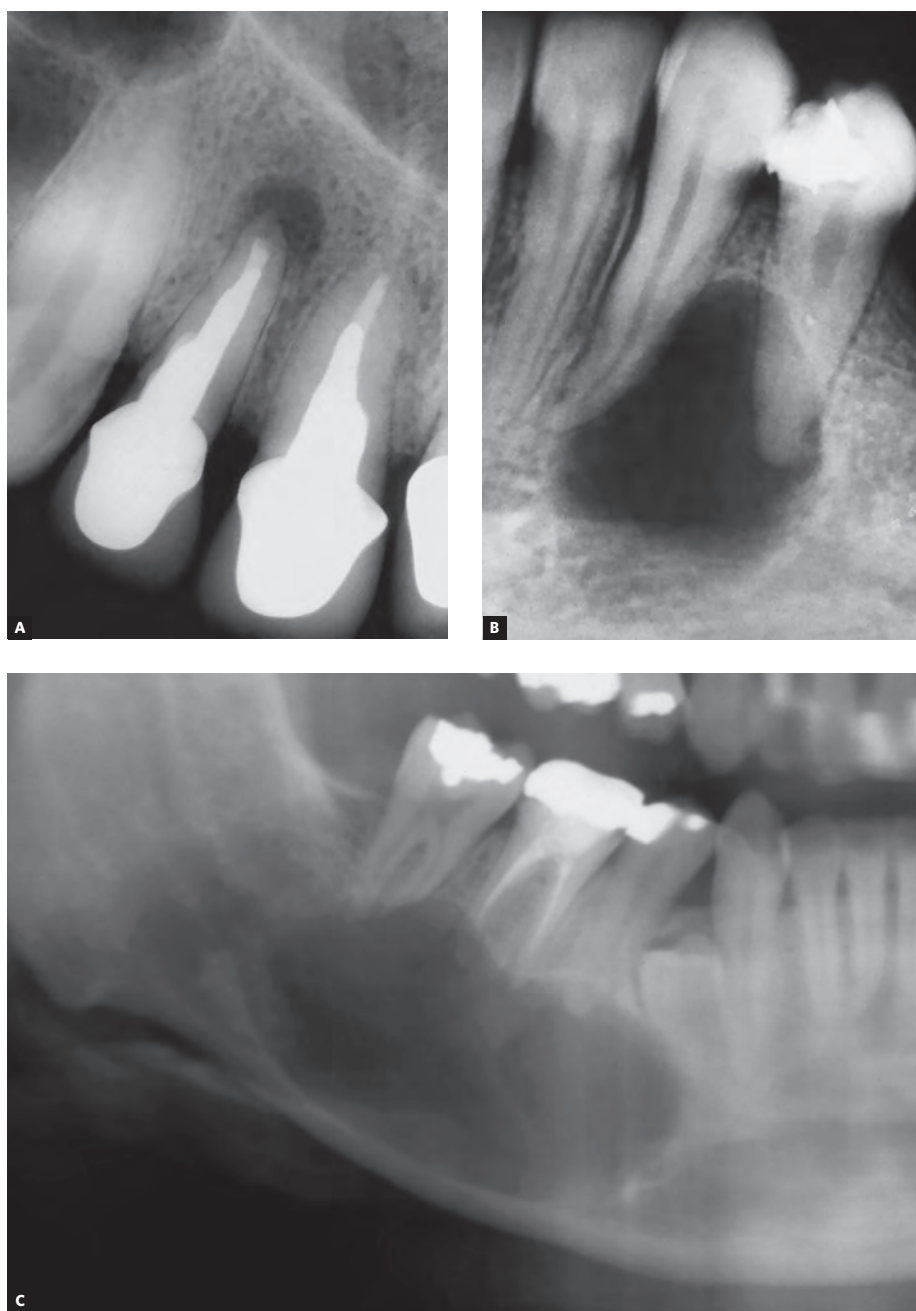


Figure 5. Odontogenic keratocysts. Note absence of root resorption and inadequate endodontic approach in **C**.

6. Ameloblastoma. Ameloblastoma might resemble a periapical lesion when the former is small (Fig 6). This is because an ameloblastoma might be found in large sizes. When it is small and confined to periapical or lateral regions of tooth roots, it is similar to an odontogenic keratocyst. Its contour tends to have convolutions, as its growth is usually multilocular.

Ameloblastoma and variations are benign odontogenic neoplasms; however, they are extremely aggressive for being invasive and having recurrent relapses. Nevertheless, ameloblastomas are asymptomatic. Additionally, they rarely cause teeth to move from their original position, but silently lead to their resorption. Whenever they are found in small and medium sizes, with up to 3-cm diameter, this is done so by chance and with the use of imaging examination required for other purposes. Only large ameloblastomas present with tumefaction and tooth mobility.

Both radiolucent lesions — ameloblastoma and odontogenic keratocyst — might be quite similar, and it is only microscopically that one can assure their differences. An important differential sign is the presence of root resorption. Should roots associated with the lesion have resorption, the chances of being an ameloblastoma are quite high (Figs 5 and 6). Should resorption not be found in roots associated with the lesion, the likelihood is that an odontogenic keratocyst was detected. In cases of ameloblastomas, root resorption is found in angulated planes, touching the lesion (Fig 6).

Ameloblastoma relapses are extremely recurrent, and removal requires a generous margin of safety to prevent further relapses. Should that be the case, af-

ected tooth/teeth will be removed along with the surgical specimen. Such an important decision requires previous incisional biopsy, since other lesions might resemble ameloblastoma in imaging examination.

Endodontists performing apical endodontic surgery have their training in surgery, which is more than enough to technically certify them to achieve ameloblastoma diagnosis. Nevertheless, the aforementioned situation might not always be convenient, whether clinically and/or professionally, for several reasons. Thus, the patient might be referred to an oral and maxillofacial surgeon whose training in surgery is more comprehensive and usually carried out in hospitals.

7. Other radiolucent lesions with or without radiopacity: in general, it will be one of several cysts and odontogenic tumors, such as glandular odontogenic cyst, botryoid odontogenic cyst, calcifying odontogenic cyst or Gorlin cyst, odontogenic fibrom, dentinogenic ghost cell tumor, central giant cell lesion, and others.

In addition to the aforementioned benign lesions, there are introsseous lesions of malignant behavior which, at early stages, might resemble chronic periapical lesions in teeth with pulp vitality. Despite being rare, those lesions are occasionally found in patients seeking endodontic treatment. Then, they become the most important fact of those patients' lives. Those lesions include odontogenic carcinoma of rare cells, spinocellular carcinoma and intraosseous mucoepithelioid carcinoma.

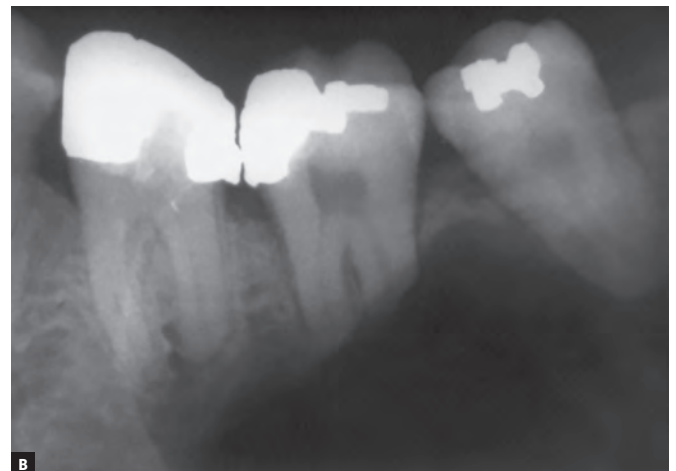
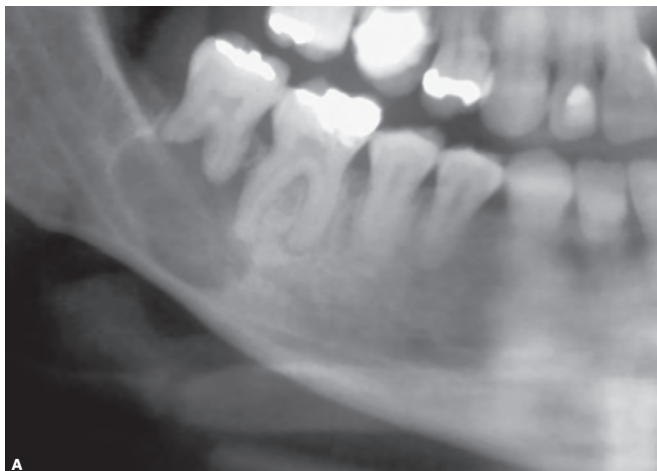


Figure 6. Ameloblastomas in periapical region of mandibular molars. Note root resorption.

The cases mentioned herein require biopsy for definite diagnosis. For clinical convenience, the endodontist might refer the patient to an oral and maxillofacial surgeon for further diagnostic approach.

Diagnosis is always the first step: Endodontic treatment is not a diagnostic tool!

In stomatologist, oral pathologist and oral and maxillofacial surgeon's clinical routine, it is not rare to find some of the aforementioned lesions, with all respective teeth presenting history of endodontic treatment carried out in sequence as an attempt to solve the lesion-related problem.

It is worth highlighting that endodontic treatment must always be considered as treatment option rather than diagnostic tool. Many clinicians claim that in cases lacking a hypothesis about endodontic diagnosis, the endodontic approach was chosen to check for lesion improvement (or even to check whether lesion had receded). Endodontic treatment must not be carried out as a therapeutic test.

Lesions that resemble chronic periapical lesions are often an oral and maxillofacial surgeon's responsibility; however, they are addressed at early or intermediate stages by the endodontist or dental surgeon.

In order to prevent mistaken protocols, the endodontist should bear in mind that no therapeutic approach should be carried out without safe clinical and imaging diagnosis reached on the basis of careful

analysis. Preference is given to an interdisciplinary approach with other experts taking part in the process of diagnosis and protocol planning. Sometimes, a "therapeutic or monitoring/follow-up attempt" ends up extending time dedicated to definite approach aimed at effective treatment. For some lesions, the evolution period is directly linked to a better or worse prognosis given to each specific case.

Final considerations

1. Teeth with pulp vitality should not be accessed without previous diagnosis of lesions. Endodontic treatment should not be carried out as diagnostic tool or therapeutic test of periapical lesions in teeth with pulp vitality.

2. Carrying out endodontic treatment in teeth with pulp vitality and lesions that resemble periapical periodontitis might extend time dedicated to an appropriate approach and, thus, considerably worsen lesion prognosis.

3. In teeth with pulp vitality and undetermined periapical lesions, it is key to establish a relationship among clinical, imaging and microscopic specialties, so as to allow for an exchange of experience and knowledge with a view to reaching safe diagnosis and carrying out effective treatment.

4. Lesions mentioned herein should be born in mind or noted down in order to allow for further application in the event of having teeth with periapical lesions and pulp vitality!

References

1. El-Naggar AK, Chan JKC, Grandis JR, Takata T, Slootweg PJ. WHO Classification of Head and Neck Tumours. WHO Classification of Tumours. 4th Edition. IARC; Lyon 2017.
2. Consolaro A. Biologia e patologia da polpa e do periápice para as especialidades clínicas. Dental Press: Maringá, 2017.

License information: This is an open-access article distributed under the terms of the Creative Commons Attribution License, which permits unrestricted use, distribution, and reproduction in any medium, provided the original work is properly cited.