

The use of the operating microscope associated with the new resources in modern endodontic microsurgery

José Mauricio Paradella de **CAMARGO**^{1,2}

Tiago **BRAGA**³

Rafael Verardino de **CAMARGO**⁴

DOI: <https://doi.org/10.14436/2358-2545.9.2.019-028.sar>

ABSTRACT

Introduction: Even when the most stringent endodontic treatment and/or retreatment are followed, apical periodontitis can persist, leading to periodontal ligament (PDL), cementum, alveolar bone and dentine destruction. In these cases, surgical endodontic treatment, if performed using the operating microscope (OM), minimal root resection, ultrasonic root end preparation and biocompatible root end filling materials, can achieve a success rate of more than 90%. Endodontic surgical procedures have been completely transformed by the incorporation of the OM with new resources, such as piezosurgery devices and specific microsurgery ultrasonic tips, flexible micromirrors, microexplorers, mini endodontic curettes,

micropluggers and micro suturing instruments. The OM can optimize all the steps of an endodontic microsurgery, including flap preparation, osteotomy, root apices identification, root end resection, inflammatory tissue removal, resected root surface observation, root end preparation, root end filling and suturing. The aim of this article is to present all the steps of modern endodontic microsurgery and to describe the new resources available in the market to improve the success rate of this modality. **Conclusion:** The use of modern endodontic microsurgery techniques significantly improves the success rates of the therapy when compared with traditional techniques.

Keywords: Endodontic microsurgery. Operating microscope. Ultrasonics, CBCT.

How to cite: Camargo JMP, Braga T, Camargo RV. The use of the operating microscope associated with the new resources in modern endodontic microsurgery. *Dental Press Endod.* 2019 May-Aug;9(2):19-28.
DOI: <https://doi.org/10.14436/2358-2545.9.2.019-028.sar>

» The authors report no commercial, proprietary or financial interest in the products or companies described in this article.

» Patients displayed in this article previously approved the use of their facial and intraoral photographs.

¹Associação dos Cirurgiões-Dentistas de Campinas (Campinas/SP, Brazil).

²Instituto Grisi de Odontologia (Ribeirão Preto/SP, Brazil).

³Griffith University, School of Dentistry and Oral Health (Gold Coast/QLD, Australia).

⁴Universidade de São Paulo, Faculdade de Odontologia de Ribeirão Preto, Departamento de Odontologia Restauradora, Endodontia (Ribeirão Preto/SP, Brazil).

Submitted: November 28, 2018. Revised and accepted: February 23, 2019.

Contact address: Tiago Braga
E-mail: t.braga@griffith.edu.au

Introduction

Advances in endodontics over the past 20–30 years have been widespread and far-reaching. In the late 1980s, San Diego endodontist Dr. Gary Carr concluded that the incredible magnification and illumination made possible with the microscope could be of benefit to the discipline of endodontics, and he started promoting the usage of the operating microscope (OM) as a crucial piece of the armamentarium used in the improvement of outcomes for endodontic apical surgeries.¹ Since then, the use of the OM has been enabling endodontists to resolve nonsurgical and surgically-challenging treatments that were previously unrecognized or untreatable, helping patients retain teeth that would have been extracted in the past.²

Different models of microscopes are available in the market, providing adjustable magnification ranging from approximately 2x–25x. Magnification can be divided into low magnification (~2x–8x), mid magnification (~8x–16x), and high magnification (~16x–25x). Low, mid and high magnification are applicable for different procedural steps throughout nonsurgical and surgical endodontic treatment. Low magnification is mainly applicable for an overview of the operating field, for local anesthesia and for rubber dam placement. Mid magnification is used for the main procedural steps throughout root canal therapy and endodontic surgery. High magnification is used for the identification of minute structures and documentation of the finest details.³ Despite the fact that high magnification increases a practitioner's accuracy, there is a learning curve, and working at both mid and high magnification will require the practitioner to slow his/her movements to avoid unintended actions on the smallest of anatomical structures. New types of instruments have been developed to allow the endodontists to work in a small-scale environment for surgical procedures, such as ultrasonic tips, flexible micromirrors, microexplorers, mini endodontic curettes, micropluggers, Stropko irrigators/driers, micro suturing instruments, etc.^{3,4}

With the OM, the clinician is able to practice while looking straight ahead without having to either bend forward in an effort to see better (causing lower back pain) or raise the patient horizontally in order to bring the oral cavity closer to the clinician (causing neck pain).^{5,6} A survey performed among general practitio-

ners revealed that the most frequent reason to retire prematurely was musculoskeletal disorders.⁷ Thus, better ergonomics conferred by magnification devices can prevent postural issues that are inherent to dentists throughout their careers. The microscope allows for 100% of the retina to be focused on the site.⁸

The OM, with an addition of a beam-splitting device and a digital or video camera, enables the clinician to efficiently capture and share with patients what is seen during an examination pre-operatively, intra-operatively and post-operatively and stored in patients chart. This practice can lead to greater rates of case acceptance, increasing patient's level of trust and confidence and significantly decreasing the amount of time required in gaining it.⁹ It has been shown that as much as 55% of the understanding that occurs in verbal communication with patients is through visual cues, and only 7% of the comprehension comes from the words we use. Stated differently, patients remember more of what they see, and what they see is what they hear.¹⁰ Digital documentation can be used for medico-legal, insurance, patient communication, and lecturing purposes and reports.⁹

Endodontic surgical procedures have been completely transformed by the incorporation of the OM combined with the use of ultrasonic tips, micro instruments and biocompatible filling materials, changing the classic apicectomy into modern endodontic microsurgery.¹¹ The OM can optimize all the steps of an endodontic microsurgery, including flap preparation, osteotomy, identification of root apices, root end resection, inflammatory tissue removal, observation of the resected root surface, root end preparation, root end filling and suturing.¹²

Cone-beam computed tomography (CBCT) has revolutionized dental imaging. Traditional periapical X-rays can only provide 2-dimensional images, while CBCT provides 3-dimensional images with excellent resolution, using a relatively low dose of radiation.^{13,14} The American Association of Endodontists and the American Academy of Oral and Maxillofacial Radiology have suggested CBCT as the imaging modality of choice for complex treatments.¹⁵ Hence, the use of this imaging modality has increased in the field of endodontics for diagnosis, treatment planning, pre- and post-operative evaluation, and management of complex endodontic microsurgery.¹⁶

The aim of this article is to present all the steps of modern endodontic microsurgery and to describe the new resources available in the market to improve the rate of success of this modality.

Preoperative procedures

To begin surgical planning, complete anamnesis, clinical, radiographic and tomographic examinations and blood tests are performed, including fasting glucose, prothrombin time and complete blood count.

Operative procedures

The first operative procedure is extraoral antisepsis with 2% chlorhexidine gluconate and placement of the fenestrated surgical drape on the patient. Anesthesia is performed to obtain analgesia and hemostasis, and then the incision is made with a microblade. The mucoperiosteal soft tissue flap should be raised atraumatically in order to obtain a complete view of the area to be operated. To keep the flap away during the entire surgery, it is important to choose the most

suitable retractor, and in some cases, it is necessary to work with two retractors at the same time.

Following the surgical steps, we performed the osteotomy that aims to obtain visualization of the apex of the involved tooth. For this step, we can use two techniques: the use of slow speed spherical burs and specific surgical ultrasonic tips. If we choose the first technique, we select a compatible bur, size (2, 4 or 6), under copious saline solution irrigation. For the ultrasonic techniques, we can use piezosurgery instruments (Fig 1) or conventional piezoelectric ultrasonic devices. If the second option is chosen, it is important to use copious saline solution irrigation.

After performing the osteotomy, we must remove the pathologic lesion or foreign body from the apical region using a molt-type curette, and we always seek to remove the lesion completely through enucleation. The final size of the osteotomy should be sufficient for visualization with magnification of the apex. The next step is the apicectomy. In order to do this, there

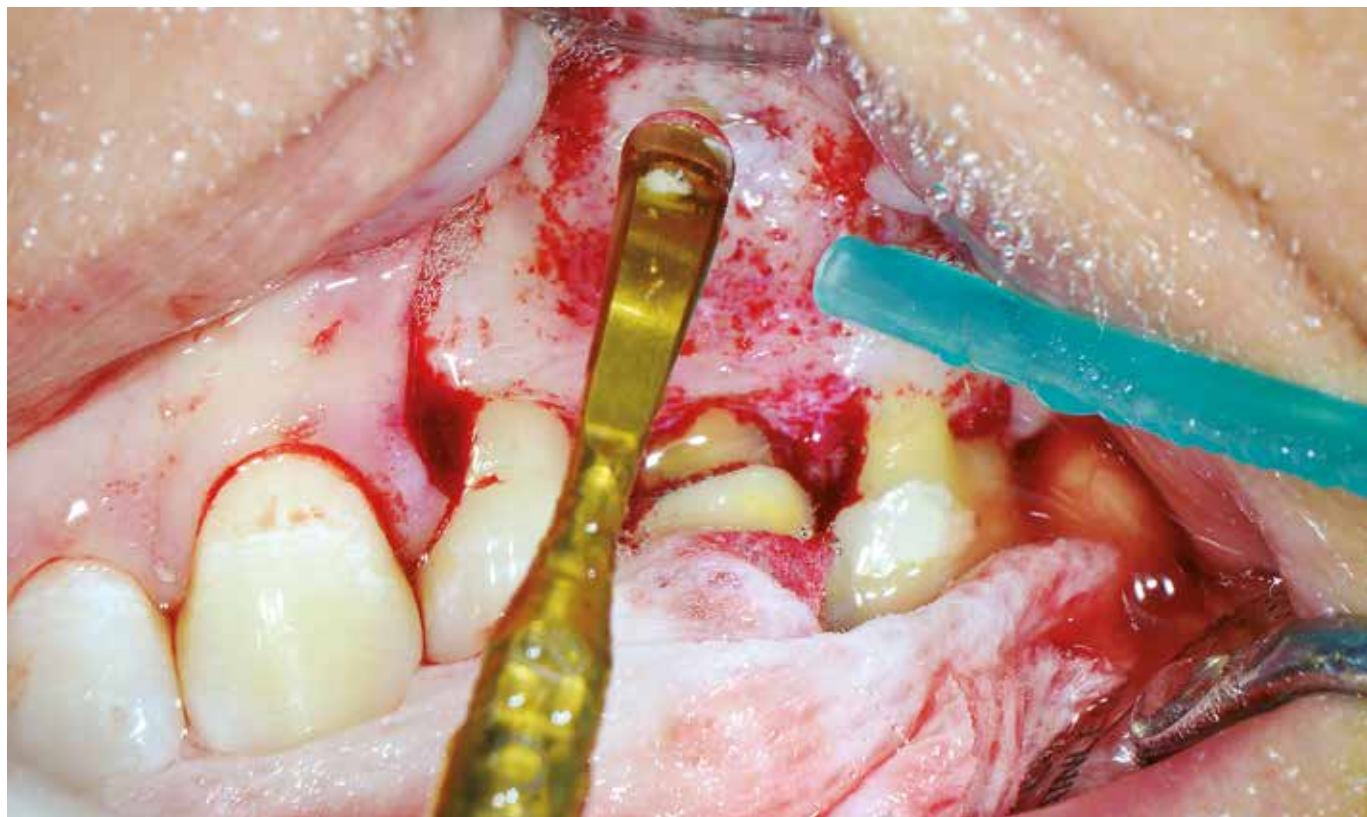


Figure 1. Osteotomy being performed with piezosurgery device and ultrasonic tip P20 Helse Ultrasonic (Santa Rosa de Viterbo, Brazil).

are three techniques: the use of high-speed burs, the use of slow-speed burs and the use of ultrasonic tips (Fig 2). Regardless of the technique, a cut should be made approximately 3 mm from the apex; this length can be adjusted according to each case. After cutting, an apical plasty should be performed with a special apical root file (Fig 3, instruments M Camargo 10 and 11) to smooth and round the entire apical portion.

To have complete visualization of this area, it is essential to use surgical micromirrors with excellent reflective quality (Fig 4). Before performing the retro-

preparation, a foraminal microexplorer should be used to locate, identify and verify the long axis of the root canal (Fig 3, instruments M Camargo 1–7). After this, we select the ultrasonic root end tip that best suits the diameter of the canal (Figure 5). It is important to verify, with a micromirror, the complete removal of obturation material and test the adaptation of the most suitable microplugger in the prepared cavity. After retro-preparation and before the root end filling, photodynamic therapy (PDT) is indicated, thus ensuring greater disinfection of the apex and surgical cavity (Figs 6 and 7).

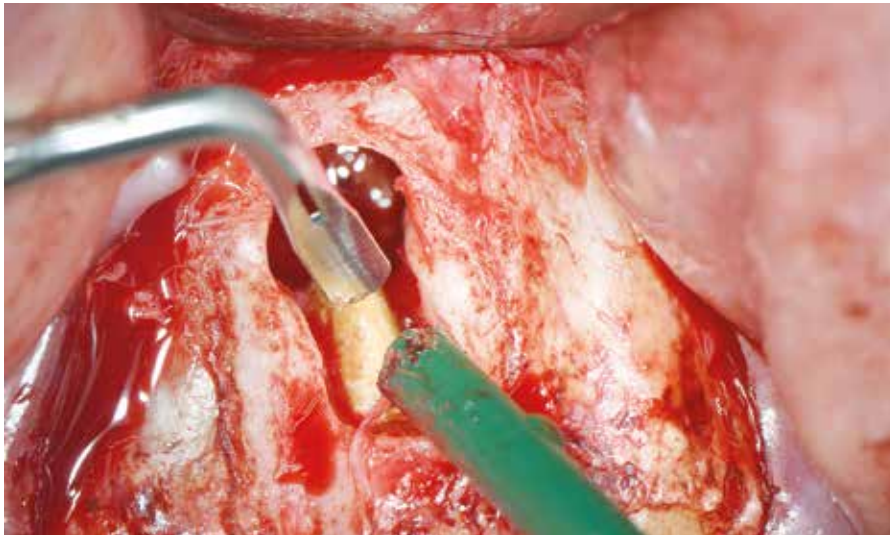


Figure 2. Bladesonic endodontic surgical tip P1B Helse Ultrasonic (Santa Rosa de Viterbo, Brazil) initiating the apicectomy.



Figure 3. Microsurgery apical instruments Kit M Camargo.

With the aid of small paper points, the retro-cavity is dried and the root end filling material is prepared, being carried to the canal with a specific carrier (Fig 3, instruments M Camargo 8 and 9). At this stage, the material must be condensed with the microplugger previously selected (Figure 3, instruments M Camargo 1–7), and a periapical X-ray is taken to verify complete filling of the canal.

Depending on the type and size of the bone defect, guided tissue regeneration (GTR), using biomaterial

grafts and membranes (Figs 8 and 9), as well as bioactive host modulating agents, to assist in the repair process is indicated. The last procedure is the suturing, and the micro instruments are essential to enable the use of surgical thread sizes 6.0 and 7.0. The flap should be repositioned, followed by the suture. The most commonly used suture is the simple interrupted suture; however, in some cases, we have to choose different suturing techniques.

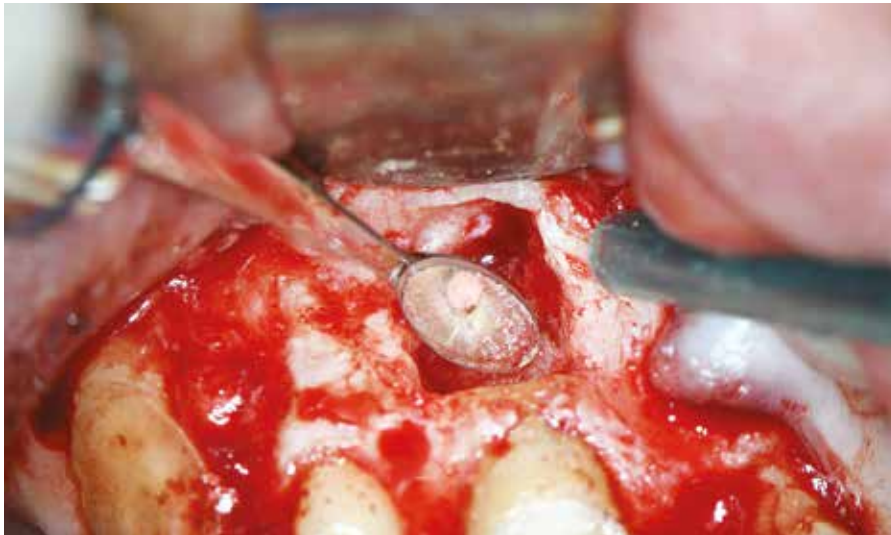

Figure 4. With the aid of a 3 mm diameter micromirror Gary Carr (San Diego, USA), it is possible to evaluate the conditions of the remaining root structure and the quality of the obturation.

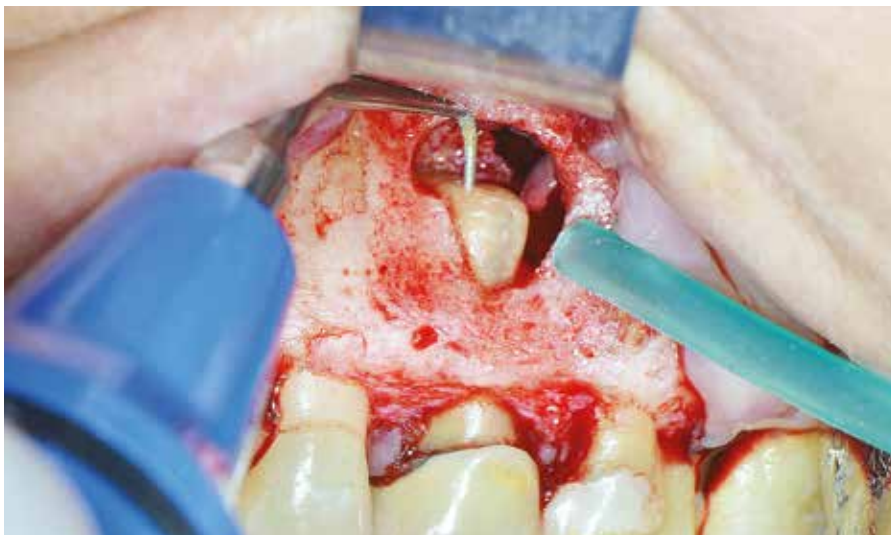

Figure 5. Ultrasonic root end preparation being performed with the ultrasonic tip P1M Helse Ultrasonic (Santa Rosa de Viterbo, Brazil) and irrigation with saline solution.

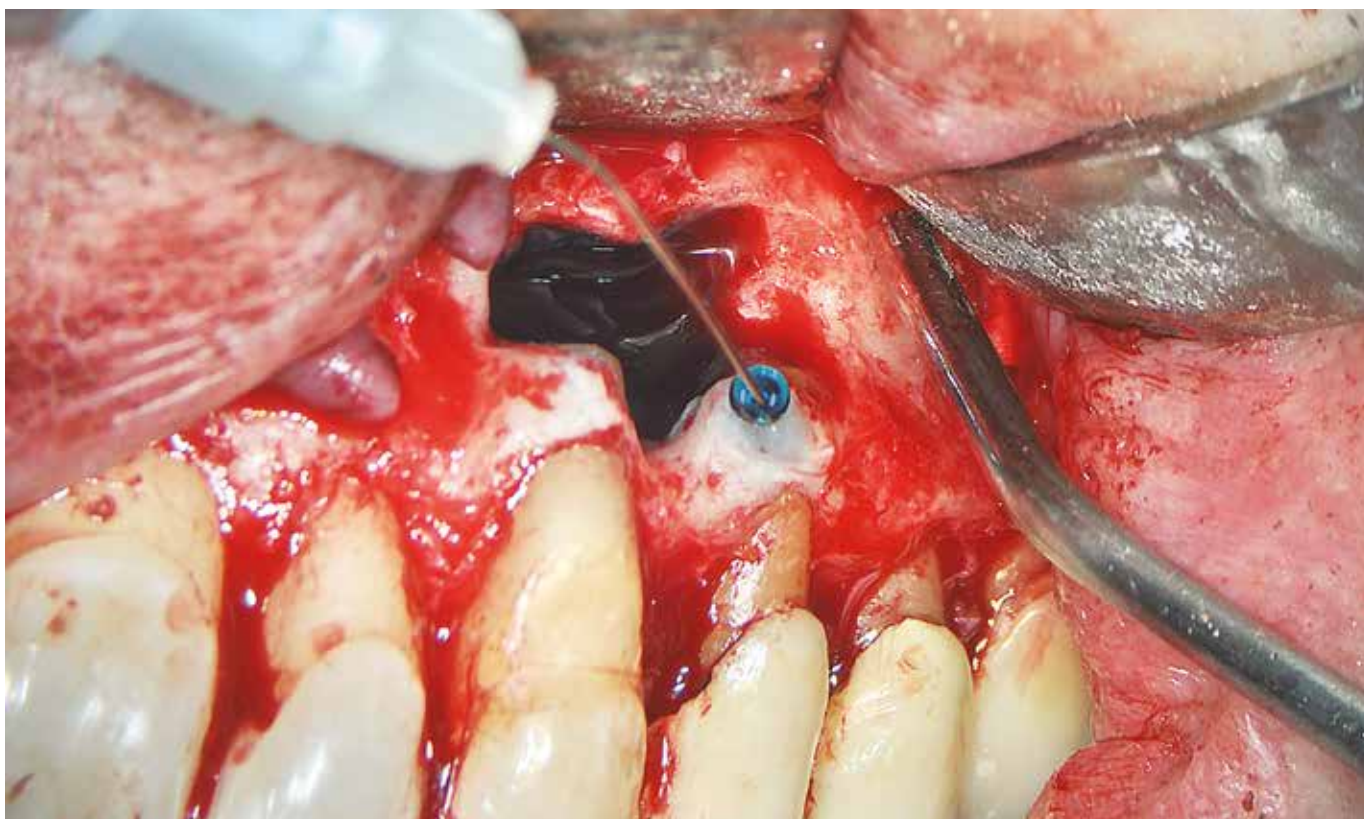


Figure 6. 0.005% methylene blue prepared in cartridges being applied to the surgical cavity with a dental carpule syringe.

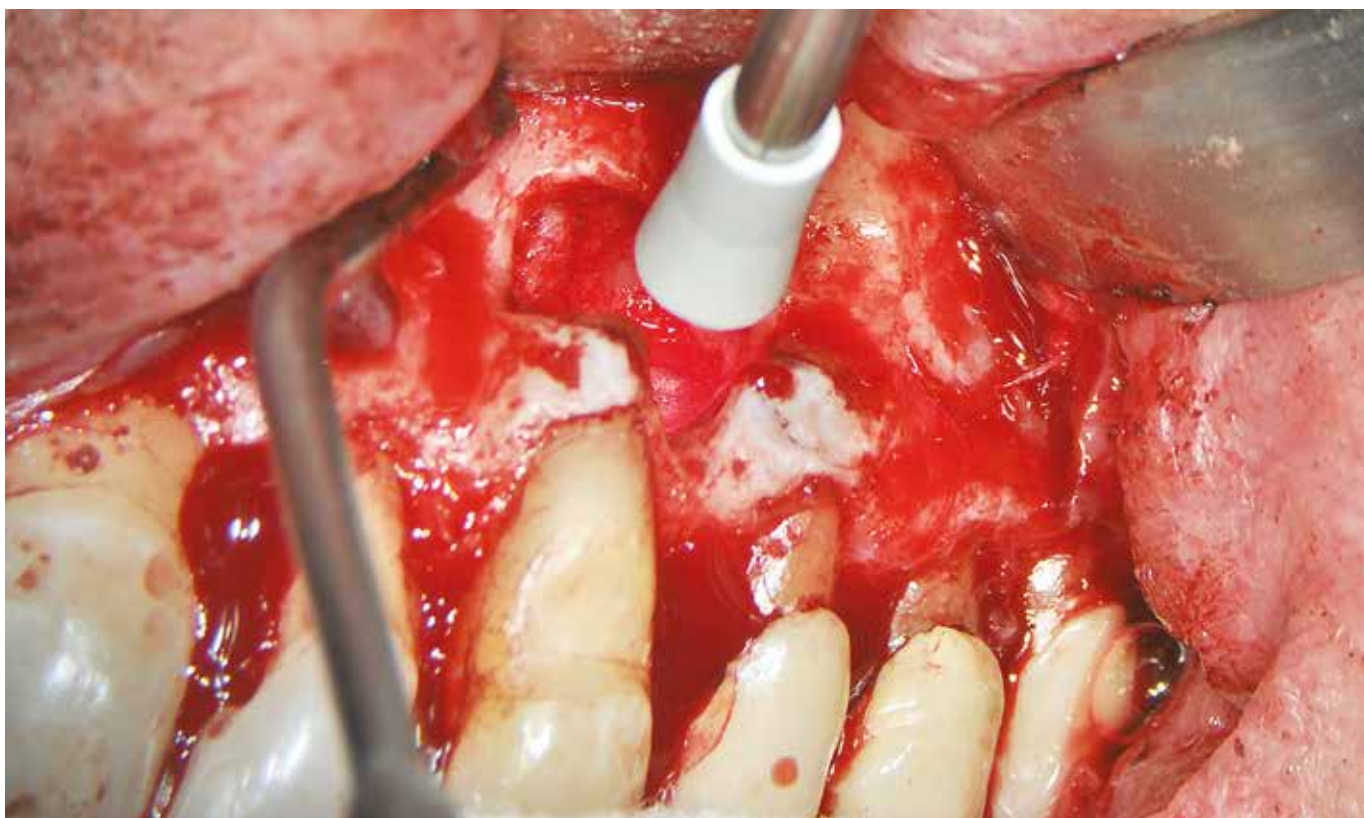

Figure 7. Photodynamic therapy (PDT) with the use of a DMC laser (São Carlos, Brazil).

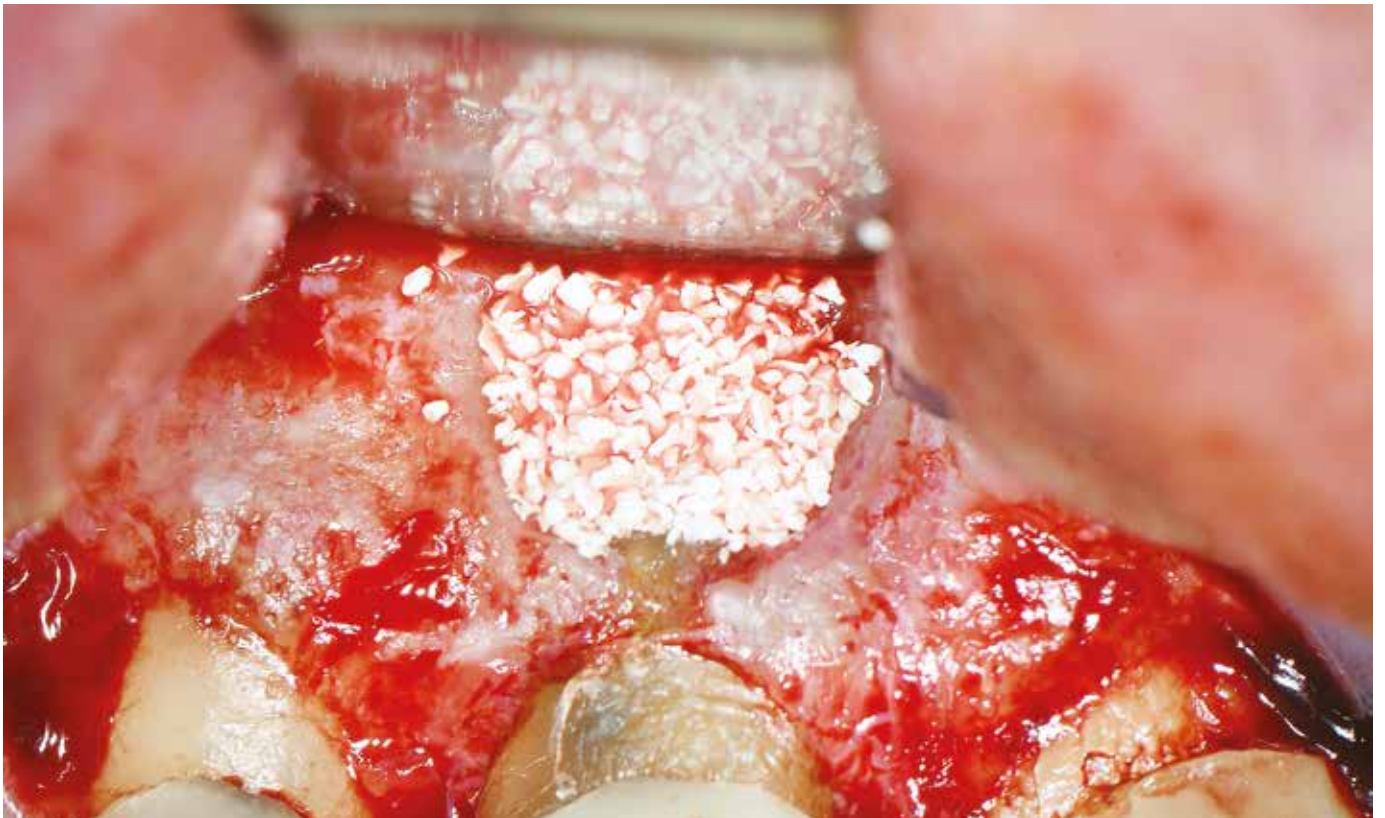

Figure 8. Surgical cavity completely filled with Bio-Oss (Geistlich, Switzerland).

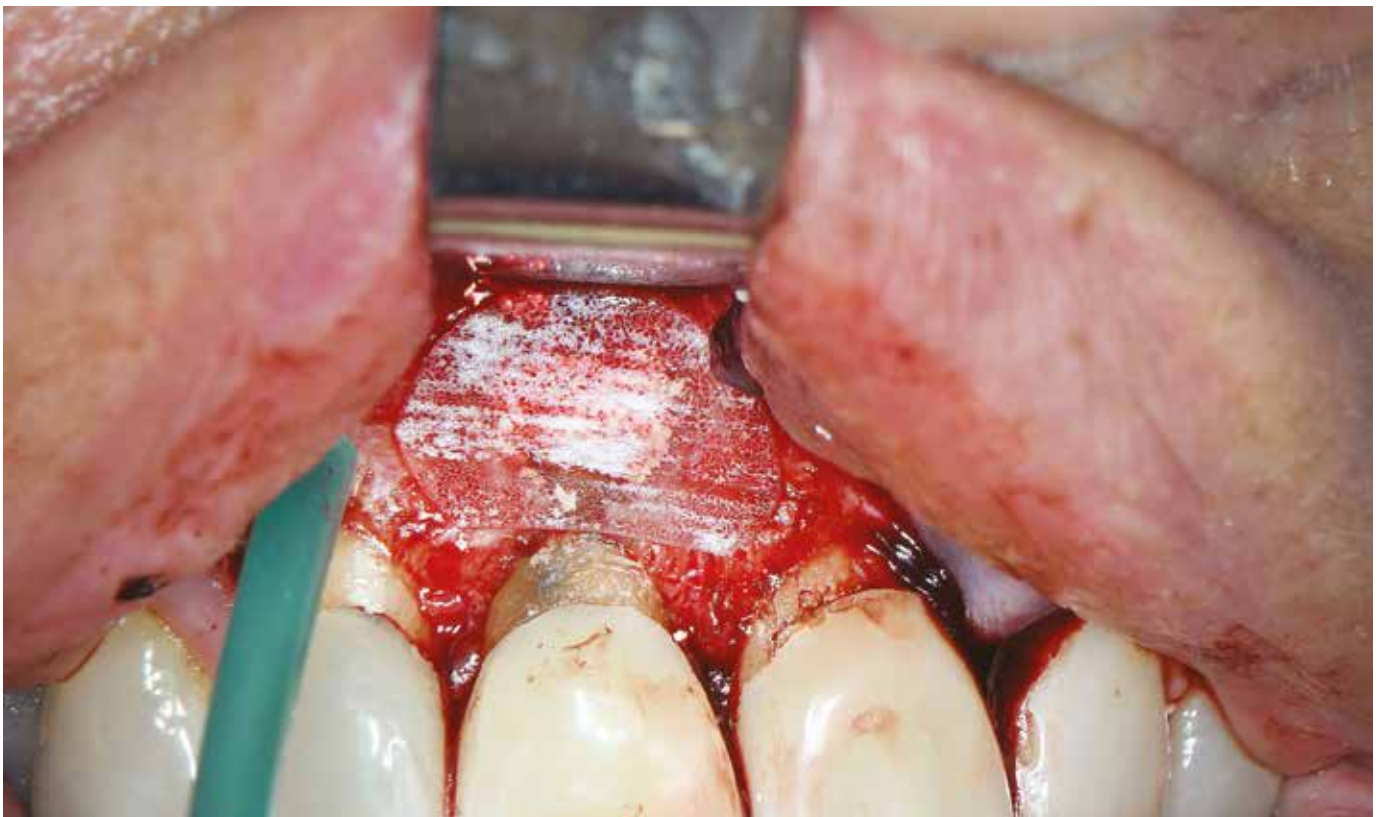

Figure 9. GenDerm membrane Baumer (Mogi Mirim, Brazil) protecting the graft material.

Discussion:

Several studies have shown that the OM has become a hallmark of the modern endodontic office.^{17,18,19} Carr²⁰ has stated that “the microscope is simply an avenue for greater competence and that there are some procedures that can only be performed with a microscope and almost all procedures are performed more competently using a microscope.” Castellucci¹⁷ has remarked that “the introduction and use of the OM in endodontics represents a qualitative leap for the profession.”

Even though the OM is now recognized as a powerful adjunct in endodontics, it has not been universally adopted by all endodontists. The OM is seen by many endodontists as simply another tool and not as a way of practice that defines how an endodontist works. Despite the fact that cost is frequently mentioned as the major impediment, in truth, it is not cost but a failure to understand and implement the positional and ergonomic skills necessary to effectively use an OM. There is an ergonomic flow to using an OM efficiently, and careful operator design is critical in enabling this flow. Many clinicians struggle with using the OM for all procedures mainly due to the fact that the ergonomic design of the operator prohibits it, which can result in significant frustration. In addition, some clinicians do not understand that having the micro instruments is fundamental for using this technology appropriately.²¹

One of the most important indications for CBCT is microsurgical procedure planning. The software allows the clinician to make all the necessary measurements, such as where to initiate the osteotomy if a bony fenestration is not present; utilize root length and thickness of cortical bone; and clearly identify anatomical structures, such as mental foramen, mandibular canal, sinus cavity, proximity of periapical lesions with adjacent vital teeth, etc. These measurements can guide the clinician throughout the surgery, avoiding complications and increasing predictability.³

The use of microblades for the incision of the microsurgical flap, micro instruments for surgical soft tissue management and micro suturing instruments is also greatly enhanced by a microscopic approach, leading to faster healing and less traumatic soft tissue management. Following these techniques is pivotal to minimize trauma and rapidly lead to the primary

goal of wound healing with less post-operative pain and complications as well as a much better prognosis than traditional procedures.²²

In cases of removal of the cortical plate, osteotomy to expose the root end is another step of endodontic microsurgery that can be performed more safely and precisely with piezosurgery devices combined with the OM. The main advantage of piezosurgery instruments include their ability to selectively cut bone atraumatically using ultrasonic vibrations without damaging adjacent soft tissue, providing a clear operative field, and cutting without generating heat.²³ The OM plays an important role in the osteotomy, helping to clearly distinguish the root tip from surrounding bone. The root is darker, yellowish and harder, whereas the bone is white, soft and bleeds when scraped with a probe. For cases where the root tip cannot be distinguished from the surrounding tissues, a high magnification can be used. Additionally, the osteotomy site can be stained with methylene blue, which usually stains the periodontal ligament to help delimitate the root.³

The piezoelectric ultrasonic instruments are one of the most significant advancements in endodontic microsurgery. Recently, the Bladesonic (P1B) endodontic surgical tip was released by Helse Ultrasonic (Santa Rosa de Viterbo, Brazil); this tip is indicated to perform root resection. For many years, this procedure has been performed with burs, which requires smoothing of the remaining root due to the rough surface left by the bur; in addition, it is more difficult to control the precision of the cut.²⁴ The root resection performed with the Bladesonic under magnification provides a precise resection, preserving root structure. Several ultrasonic tips were designed for the retropreparation, according to the size and angle of the canal. There are also custom surgical tips that can be bent once or twice at any angle and direction needed. The advantages include microprojection of the cutting surface, allowing quick and complete removal of gutta percha from the canal, more conservative retropreparation and preparation of the isthmus. In addition, the new techniques result in a significantly smaller osteotomy, as the retropreparation tips can be used even in small surgical cavities of 4 mm in diameter.^{3,25}

Photodynamic therapy (PDT) has become a promising approach to improve disinfection during endodontic surgical procedures.²⁶ PDT uses light of

a specific wavelength to activate a nontoxic photoactive dye (methylene blue) in the presence of oxygen. According to Vieira et al,²⁷ the use of PDT during endodontic surgery significantly enhanced disinfection of the cut surface area and root end cavity, increasing the healing rate.

Different materials have been used for retrograde root filling in endodontic microsurgery, such as, IRM, super EBA, MTA and Bioceramic root repair putty. The use of Bioceramic fast set putty as a root end filling material has shown to be a great option; it presents excellent mechanical and biological properties and easy handling, and it is hydrophilic, insoluble, radiopaque, and aluminum-free. In addition, this putty has a high pH and requires moisture to set and harden. The working time of the putty is approximately 20 minutes, and the setting time is 4 hours in normal conditions, depending on the amount of moisture available.²⁸⁻³⁰

GTR techniques involve the use of bone replacement grafting materials, barriers or membranes and bioactive host modulating agents to prevent the invagination of connective/epithelial tissue into the bone defect area and to maximize the body's healing potential to regenerate.^{31,32} This technique is indicated for through-and-through defects, including sinus perforation, large lesions greater than 10 mm in diameter, endo/perio communication, loss of buccal plate, dehiscence, denuded root and furcal involvement.³ Taschieri et al.³³ evaluated the efficacy of guided tissue regeneration in the management of through-and-through lesions following surgical endodontics. The

outcomes showed that defects treated with GTR (Bio-Oss combined with BioGuide membrane) (Geistlich, Switzerland) had an 88% success rate compared to the control group (without GTR), which had a success rate of only 57%. Dominiak et al.³⁴ suggested that combining GTR with the use of platelet-rich plasma (PRP) increases the success rate up to 92%. Several clinical studies revealed that platelet-rich fibrin (PRF) in the form of a platelet gel can be used in conjunction with bone grafts, which has several advantages, such as promoting wound healing, bone growth and maturation, wound sealing and hemostasis, and imparts better handling properties to graft material. In addition, the use of PRF reduced the healing time, resulting in faster bone regeneration.³⁵⁻³⁷

Setzer et al.³⁸ investigated the outcome of traditional root end surgery versus modern endodontic microsurgery. When the procedure was performed under magnification with modern microsurgical methods, the success rate was 94%, as opposed to 59% when performed with neither magnification nor cutting-edge instruments. This difference was statistically significant ($P < .0005$). The relative risk ratio showed that the probability of success for modern endodontic microsurgery was 1.58 times the probability of success for traditional root end surgery.

Conclusion

The use of modern endodontic microsurgery techniques significantly improves the success rates of the therapy when compared with traditional techniques.

References

- Carr GB. Microscopes in Endodontics. *J Calif Dent Assoc.* 1992;20(11):55-61.
- AAE Position Statement. Use of microscopes and other magnification techniques. *J Endod* 2012 Aug;38(8):1153-5.
- Kim S, Kratchman S, Karabucak B, Kohli M, Seltzer FC. The dental operating microscope. In: *Microsurgery in Endodontics*. Hoboken: John Wiley & Sons; 2018.
- Setzer FC. The dental operating microscope in endodontics. *AAE Colleagues for Excellence.* 2016 Winter;2:1-8.
- Kumar UD, Subhasis D. Dental Operating Microscope in Endodontics: a review. *IOSR J Dent Med Sci.* 2013;5(6)1-8.
- Low JF, Mohd Dom TN, Baharin SA. Magnification in endodontics: A review of its application and acceptance among dental practitioners. *Eur J Dent.* 2018 Oct-Dec;12(4):610-6.
- Brown J, Burke FJ, Macdonald EB, Gilmour H, Hill KB, Morris AJ, et al. Dental practitioners and ill health retirement: Causes, outcomes and re-employment. *Br Dent J.* 2010 Sept 11;209(5):E7.
- van AS GA. Extreme magnification: seeing the light. Available from: www.ineedce.com
- Napoletano D. The Dental Operating Microscope: The most valuable (and profitable) technology a dentist can own. *Inside Dent.* 2010 Feb;6(2).
- van AS GA. Digital Documentation and the Dental Operating Microscope: what you see is what you get. *Int J Microdent.* 2009;1:30-41.
- Rubinstein RA, Kim S. Short-term observation of the results of endodontic surgery with the use of a surgical operation microscope and super-EBA as root-end filling material. *J Endod.* 1999 Jan;25(1):43-8.
- Kim S, Kratchman S. Modern endodontic surgery concepts and practice: a review. *J Endod.* 2006 July;32(7):601-23.
- Studebaker B, Hollender L, Mancl L, Johnson JD, Paranjpe A. The incidence of second mesiobuccal canals located in maxillary molars with the aid of cone-beam computed tomography. *J Endod.* 2018 Apr;44(4):565-70.
- Kamburoglu K, Yilmaz F, Gulsahi K, Gulen O, Gulsahi A. Change in Periapical lesion and adjacent mucosal thickening dimensions one year after endodontic treatment: volumetric cone-beam computed tomography assessment. *J Endod.* 2017 Feb;43(2):218-24.
- Special Committee to Revise the Joint AAE/AAOMR Position Statement on use of CBCT in Endodontics. AAE and AAOMR joint position statement. Use of cone beam computed tomography in endodontics 2015 update. *J Endod.* 2015 Sept;41(9):1393-6.
- Patel S, Durack C, Abella F, Shemesh H, Roig M, Lemberg K. Cone beam computed tomography in endodontics: a review. *Int Endod J.* 2015;48(1):3-15.
- Castellucci A. Magnification in endodontics: the use of the operating microscope. *Pract Proced Aesthet Dent.* 2003 June;15(5):377-84; quiz 386.
- Kim S. Modern endodontic practice: instruments and techniques. *Dent Clin North Am.* 2004 Jan;48(1):1-9.
- Garcia A. Dental magnification: a clear view of the present and a close-up view of the future. *Compend Contin Educ Dent.* 2005 June;26(6A Suppl):459-63.
- Carr GB. Endodontics at the crossroads. *J Calif Dent Assoc.* 1996 Dec;24(12):20-6.
- Carr G, Murgel C. The use of operating microscopes in endodontics. *Dent Clin North Am.* 2010 Apr;54(2):191-214.
- Velvart P, Peters CI. Soft tissue management in endodontic surgery. *J Endod.* 2005 Jan;31(1):4-16.
- Abella F, de Ribot J, Doria G, Duran-Sindreu F, Roig M. Applications of piezoelectric surgery in endodontic surgery: a literature review. *J Endod.* 2014 Mar;40(3):325-32.
- Nedderman TA, Hartwell GR, Protell FR. A comparison of root surfaces following apical root resection with various burs: scanning electron microscopic evaluation. *J Endod.* 1988 Sept;14(9):423-7.
- Carr GB. Ultrasonic root end preparation. *Dent Clin North Am.* 1997 July;41(3):541-54.
- Garcez AS, Arantes-Neto JG, Sellera DP, Fregnani ER. Effects of antimicrobial photodynamic therapy and surgical endodontic treatment on the bacterial load reduction and periapical lesion healing. Three years follow up. *Photodiagnosis Photodyn Ther.* 2015 Dec;12(4):575-80.
- Vieira GCS, Antunes HS, Pérez AR, Gonçalves LS, Antunes FE, Siqueira JF Jr, et al. Molecular analysis of the antibacterial effects of photodynamic therapy in endodontic surgery: a case series. *J Endod.* 2018 Oct;44(10):1593-7.
- Trope M, Bunes A, Debelian G. Root filling materials and techniques: bioceramics a new hope? *Endod Topics.* 2015;32:86-96.
- Candeiro GT, Correia FC, Duarte MA, Ribeiro-Siqueira DC, Gavini G. Evaluation of radiopacity, pH, release of calcium ions, and flow of a bioceramic root canal sealer. *J Endod.* 2012 June;38(6):842-5.
- Wang Z. Bioceramic materials in endodontics. *J Istanbul Univ Fac Dent.* 2017;51(3 Suppl 1):S128-37.
- Artzi Z, Wassersprung N, Weinreb M, Steigmann M, Prasad HS, Tsesis I. Effect of guided tissue regeneration on newly formed bone and cementum in periapical tissue healing after endodontic surgery: an in vivo study in the cat. *J Endod.* 2012 Feb;38(2):163-9.
- Nair PN, Sjögren U, Figdor D, Sundqvist G. Persistent periapical radiolucencies of root-filled human teeth, failed endodontic treatments, and periapical scars. *Oral Surg Oral Med Oral Pathol Oral Radiol Endod.* 1999;87(5):617-27.
- Taschieri S, Del Fabbro M, Testori T, Saita M, Weinstein R. Efficacy of guided tissue regeneration in the management of through-and-through lesions following surgical endodontics: a preliminary study. *Int J Periodontics Restorative Dent.* 2008 June;28(3):265-71.
- Dominiak M, Lysiak-Drwal K, Gedrange T, Zietek M, Gerber H. Efficacy of healing process of bone defects after apicectomy: results after 6 and 12 months. *J Physiol Pharmacol.* 2009 Dec;60 Suppl 8:51-5.
- Agarwal A, Gupta N D, Jain A. Platelet rich fibrin combined with decalcified freeze-dried bone allograft for the treatment of human intrabony periodontal defects: a randomized split mouth clinical trial. *Acta Odontol Scand.* 2016;74(1):36-43.
- Inchingolo F, Tatullo M, Marrelli M, Inchingolo AM, Scacco S, Inchingolo AD, et al. Trial with platelet-rich fibrin and Bio-Oss used as grafting materials in the treatment of the severe maxillary bone atrophy: clinical and radiological evaluations. *Eur Rev Med Pharmacol Sci.* 2010;14(12):1075-84.
- Castro AB, Meschi N, Temmerman A, Pinto N, Lambrechts P, Teughels W, et al. Regenerative potential of leucocyte- and platelet-rich fibrin. Part B: sinus floor elevation, alveolar ridge preservation, and implant therapy. A systematic review. *J Clin Periodontol.* 2017;44(2):225-34.
- Setzer FC, Shah SB, Kohli MR, Karabucak B, Kim S. Outcome of endodontic surgery: A meta-analysis of the literature – Part 1: Comparison of traditional root-end surgery and endodontic microsurgery. *J Endod.* 2010 Nov;36(11):1757-65.