

# Non-surgical treatment for removing fractured instrument and extravasated gutta-percha, by using the Masserann EndoKit

Clóvis Monteiro **BRAMANTE**<sup>1</sup>  
 Mariana Maciel Batista **BORGES**<sup>1</sup>  
 Jussaro Alves **DUQUE**<sup>1</sup>  
 Murilo de Almeida **MANOEL**<sup>1</sup>  
 Alexandre Silva **BRAMANTE**<sup>2</sup>  
 Rodrigo Ricci **VIVAN**<sup>1</sup>  
 Norberti **BERNARDINELI**<sup>1</sup>  
 Marco Antonio Hungaro **DUARTE**<sup>1</sup>

DOI: <https://doi.org/10.14436/2358-2545.9.2.071-075.oar>

## ABSTRACT

The objective of this article was to report a clinical case of finding a fractured instrument and over-extended gutta-percha of a tooth, which were removed via the canal. The patient, a 38-year-old man, was referred for treatment of the right maxillary lateral incisor (tooth 7). The patient presented pain on palpation at the apical level and absence of spontaneous symptomatology. Radiographic examination revealed the presence of a over-extended gutta-percha cone, a fractured Lentulo spiral and periapical lesion in tooth 7. Endodontic retreatment was the chosen procedure in an attempt to remove both materials. The Lentulo spiral was removed by

means of the Masserann Endokit, and the gutta-percha cone by using Hedstroen files. While performing instrumentation, and filling the canal with calcium hydroxide with iodoform, the presence of resorption in the apical third was verified. After 2 months, reduction of the lesion was observed, thus MTA was placed in the area of resorption and the remainder of the canal was filled with a gutta-percha cone and Sealer 26 cement. Clinical and radiographic controls performed after 2, 5 and 7 years showed repair of the area and absence of symptomatology.

**Keywords:** Endodontics. Calcium hydroxide. Gutta-percha. Treatment outcome.

**How to cite:** Bramante CM, Borges MMB, Duque JA, Manoel MA, Bramante AS, Viván RR, Bernardineli N, Duarte MAH. Non-surgical treatment for removing fractured instrument and extravasated gutta-percha, by using the Masserann EndoKit. *Dental Press Endod.* 2019 May-Aug;9(2):71-5.  
 DOI: <https://doi.org/10.14436/2358-2545.9.2.071-075.oar>

» The authors report no commercial, proprietary or financial interest in the products or companies described in this article.

» Patients displayed in this article previously approved the use of their facial and intraoral photographs.

Submitted: July 07, 2017. Revised and accepted: November 17, 2017.

<sup>1</sup> Universidade de São Paulo, Departamento de Dentística, Endodontia e Materiais Odontológicos (Bauru/SP, Brazil).

<sup>2</sup> Private Clinic (Bauru/SP, Brazil).

Contact address: Mariana Maciel Batista Borges  
 Rua Manoel Pereira Rolla, 11-45, Vila Universitária  
 CEP: 17.020-190 - Bauru/SP  
 E-mail: [mmborges@hotmail.com](mailto:mmborges@hotmail.com)

## Introduction

The success of endodontic treatment is related to the cure or prevention of apical periodontitis, so that the tooth remains healthy and in function in the oral cavity. The objective of endodontic therapy is attained after adequate biomechanical preparation and sealing the canals with filling material.<sup>1</sup>

Accidents such as instrument fractures and perforations can occur and generate difficulties in the biomechanical preparation and filling of the root canal system, thus negatively influencing the prognosis of treatment, especially if these accidents occur in teeth with apical periodontitis.<sup>2</sup>

While removal of the fractured instrument is an important maneuver for successful treatment, not only is it a difficult procedure but it can also be time-consuming.<sup>3</sup> Several devices used in the removal of instruments, such as ultrasound, the Masserann EndoKit, Canal Finder have been described in the literature. Some factors such as tooth anatomy, canal gauge, location, type and size of the fragment, and operator ability may influence the resolution of these cases.<sup>4</sup>

Another accident that may occur during treatment is the extrusion of sealing material, such as gutta-percha. This can generate a foreign body type of reaction, which can lead to chronic inflammation with perpetuation of the lesion and may lead to root resorption.<sup>5</sup>

The objective of this article was to present a clinical case of removing an over-extended gutta-percha cone and a Lentulo spiral fragment, by means of non-surgical retreatment.

## Case report

The patient, a 38-year-old man was referred for evaluation of the right maxillary lateral incisor (tooth 7). During the clinical examination, the patient reported pain on palpation at the apical level, but without spontaneous symptoms. In the radiographic examination the presence of an over-extended gutta-percha, a fractured endodontic instrument (Lentulo Spiral) and the presence of a periapical lesion were observed (Fig 1).

The therapeutic approach chosen was conservative non-surgical endodontic retreatment for the removal of the Lentulo spiral fragment and the extravasated filling material.

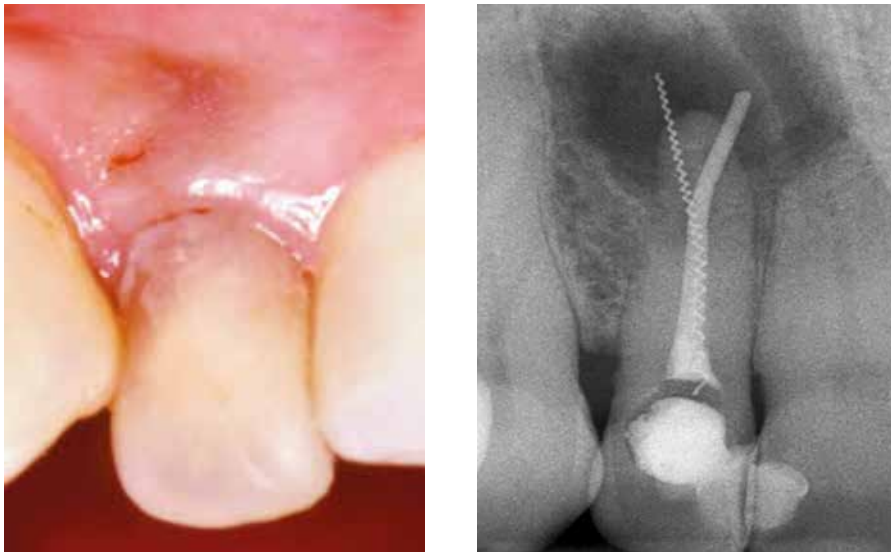
After access to the pulp cavity, the Lentulo spiral was removed by using the Masserann EndoKit device (Masserann Micro-Mega EndoKit, Besançon, France). The Masserann EndoKit is composed of Gates Glidden drills, trepan burs and tubular extractors of different calibers. The purpose of the trepan burs was to abrade the dentin around the fragment to expose an area of approximately 3 mm of it. Thereafter, the tubular extractor was introduced into this space previously created, with the aim of seizing part of the fragment (3 mm) in the extractor and removing it by rotating the assembly (device and fragment) in a counterclockwise direction. After removing the fragment, an attempt was made to remove the gutta-percha by using Hedstroem files without solvent. The Hedstroem file was introduced into the canal with clockwise rotation, in the length of the tooth, which was 23mm; a portion of the gutta-percha was detected and part of it was removed by traction. After several attempts it was possible to remove it via the canal (Fig 2).

The canal was prepared, using crown-down technique, and the final apical size was #80. During the instrumentation, the irrigant, 1% sodium hypochlorite solution, was delivered carefully and passively, avoided extrusion beyond the apex. After this, the root was filled with a calcium hydroxide paste, iodoform (ratio of 3 parts calcium hydroxide to 1 iodoform) and propylene glycol, when a large area of reabsorption was found radiographically, which justified extrusion of the gutta-percha.

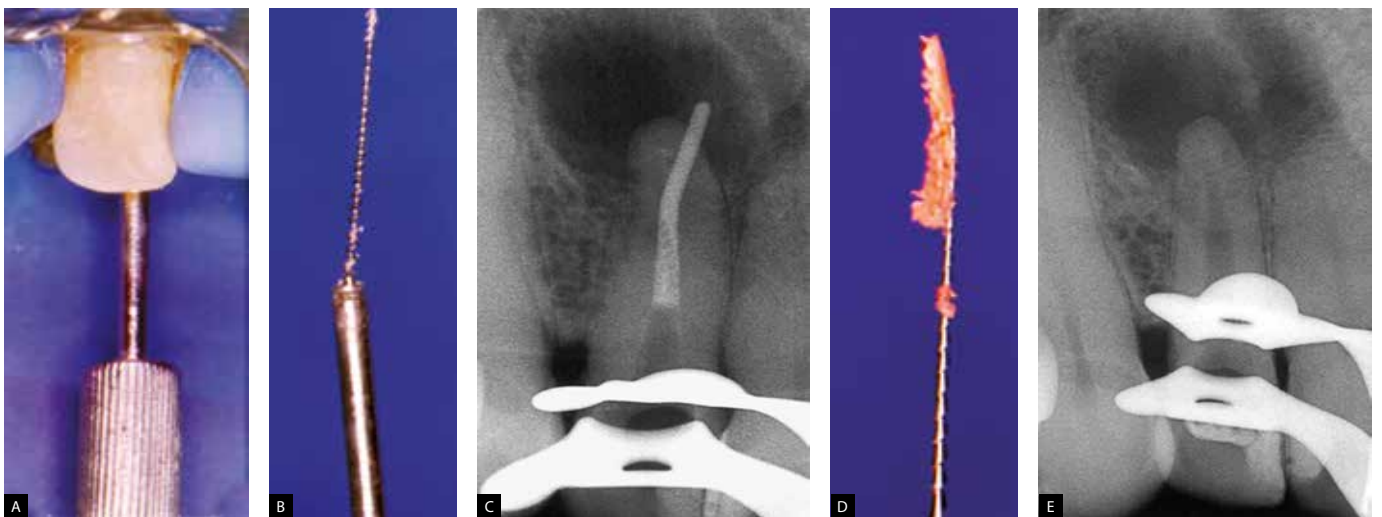
After 2 months of control and absence of symptomatology, an MTA plug (ProRoot, Dentsply Maillefer, Ballaigues, Switzerland) was made in the area of resorption. For this, the material was mixed according to manufacturer's instructions and introduced with lentulo drill, and adapted to the canal walls with Paiva's condenser.

The remaining canal was filled with gutta-percha and sealer 26 cement (Dentsply Maillefer, Ballaigues, Switzerland), with lateral condensation technique and coronal restoration was performed with glass ionomer cement.

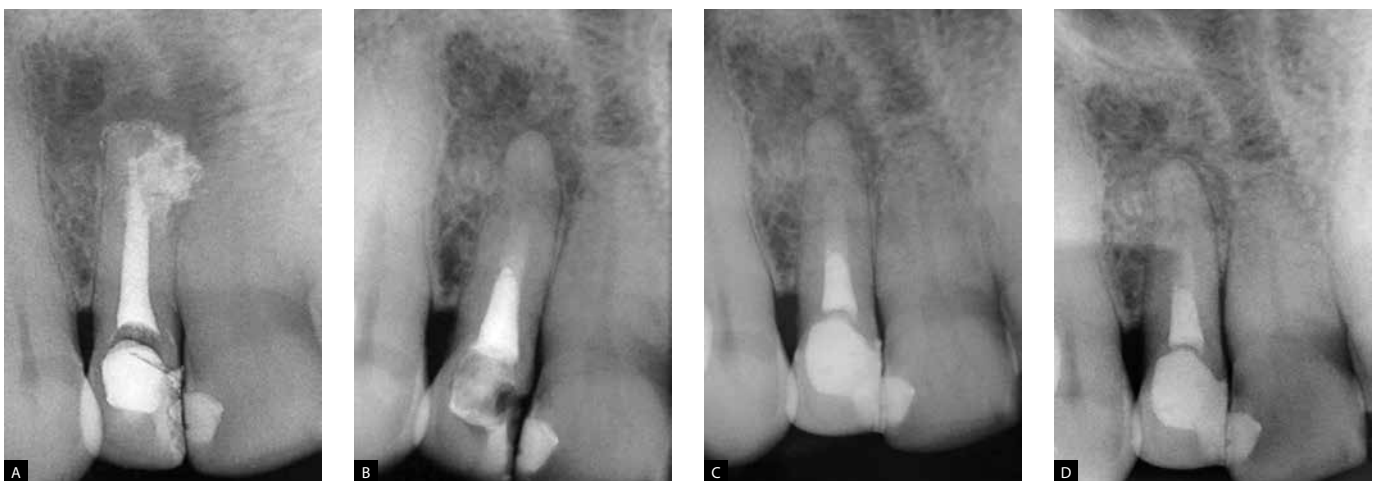
Clinical and radiographic controls at 2, 5 and 7 years showed absence of symptomatology and repair of the area (Figure 3).



**Figure 1.** Clinical and radiographic initial aspects evidencing the presence of a fractured Lentulo and over-extended gutta-percha cone.



**Figure 2.** A, B, C) Removal of fractured Lentulo with Masserann EndoKit; D, E) removal of the gutta-percha cone with Hedstroem files.



**Figure 3.** Radiography after sealing with MTA and obturation of the root canal (A) and radiographic controls after 2 (B), 4 (C) and 8 (D) years evidencing the repair of the periapical region.

## Discussion

While performing endodontic procedures, the possibility of accidents occurring, such as instrument fracture, deviations and perforations, is always present; these can be triggered by different factors, ranging from the professional's lack of skill, through to anatomical complexities.<sup>6</sup> In the study of Kerekes et al,<sup>7</sup> the authors demonstrated that the frequency of remanufactured instruments used within the canal varies from 2% to 6% and successful removal occurs in 55% to 87% of cases.<sup>2,8</sup>

Several techniques have been proposed for the removal of fractured instruments, such as use of manual files, ultrasonic inserts, the Masserann EndoKit, among others. Introduction of the microscope in Endodontics facilitated the visualization, and consequently, the removal of these fragments. There is, however, no standard form of removal, so that each case requires a different approach according to the variations present, such as the level at which the Instrument fractured, fragment size, and tooth/canal anatomy.<sup>2</sup>

Removal of extravasated filling material is another challenge in endodontic retreatment. In the present case, the over-extended gutta-percha was removed by using Hedstroem files and abundant irrigation with sodium hypochlorite. Removal of the Lentulo spiral fragment was removed with the use of the Masserann EndoKit.

The Masserann EndoKit is a system designed specifically for the removal of metal objects from the root canal and has been used for over 30 years, with a success rate of 73% in anterior teeth.<sup>9</sup> It has a limited application, since it requires extensive dentin removal around the fragment, and therefore, it is preferentially used in wide and straight canals.<sup>10</sup> Thirumalai et al.<sup>11</sup> have shown successful cases in the removal of fractured instruments from posterior teeth with curved roots by using the Masserann EndoKit, in spite of some clinical limitations.

Gerek et al.<sup>12</sup> demonstrated that although extensive dentin removal was required, the force to cause vertical fracture did not differ statistically in teeth from which the fragment was removed with an ultrasonic insert. In the present study, the use of ultrasonic inserts showed an effectiveness of approximately 80% in the removal of the fractured instrument, however, due to the high frequency of ultrasonic vibration, coronal fracture of the instrument may occur.<sup>13</sup>

In the present case, because of the canal anatomy, it was not difficult to remove the fragment with the Masserann EndoKit, and did not promote marked wear of the dentin walls. It is important to remember that the instruments that fracture in the canal are mostly threaded onto the canal walls, and therefore, when removing instrument fragments with this device, it must be rotated in a counterclockwise direction.

At first, it was difficult to understand how the gutta-percha had so easily gone beyond the apex and moved in each attempt to remove it, until the radiograph of the canal filled with the calcium hydroxide paste with iodoform showed the presence of a large area of resorption, through which the gutta-percha cone had been extruded and moved when we attempted to remove it.

Many studies have evaluated the impact on the prognosis of teeth with fractured instruments and concluded that the presence of periradicular lesion was the main factor that triggered failure.<sup>14,15</sup> In the case here reported, the tooth presented periapical radiolucency and resorption, so it was essential to remove the instrument to enable the conservative endodontic therapy procedures to be performed and achieve successful treatment.

## Conclusion

This clinical report demonstrated that many endodontic accidents can be resolved by non-surgical treatment. The Masserann EndoKit showed favorable result in the removal of fractured instrument.

## References

1. Siqueira JF, Rôças IN, Ricucci D, Hülsmann M. Causes and management of post-treatment apical periodontitis. *Br Dent J*. 2014 Mar;216(6):305-12.
2. Hülsmann M, Schinkel I. Influence of several factors on the success or failure of removal of fractured instruments from the root canal. *Endod Dent Traumatol*. 1999 Dec;15(6):252-8.
3. Hülsmann M. Methods for removing metal obstructions from the root canal. *Endod Dent Traumatol*. 1993 Dec;9(6):223-37.
4. Gencoglu N, Helvacioglu D. Comparison of the different techniques to remove fractures endodontic instruments from root canal systems. *Eur J Dent*. 2009 Apr;3(2):90-5.
5. Brooks JK, Kleinman JW. Retrieval of extensive gutta-percha extruded into the maxillary sinus: use of 3-dimensional cone-beam computed tomography. *J Endod*. 2013 Sept;39(9):1189-93.
6. McGuigan MB, Louca C, Duncan HF. The impact of fractured endodontic instruments on treatment outcome. *Br Dent J*. 2013 Mar;214(6):285-9.
7. Kerekes K, Tronstad L. Long-term results of endodontic treatment performed with a standardized techniques. *J Endod*. 1979 Mar;5(3):83-90.
8. Suter B, Lussi A, Sequeira P. Probability of removing fractured instruments from root canals. *Int Endod J*. 2005 Feb;38(2):112-23.
9. Okiji T. Modified usage of the Masserann Kit for removing intracanal broken instruments. *J Endod*. 2003 Jul;29(7):466-7.
10. Ruddle CJ. Nonsurgical retreatment. *J Endod*. 2004 Dec;30(12):827-45.
11. Thirumalai AK, Sekar M, Mylswamy S. Retrieval of a separated instrument using Masserann technique. *J Endod*. 2004 Dec;30(12):827-45.
12. Gerek M, Baser ED, Kayahan MB, Sunay H, Kaptan RF, Bayirli G. Comparison of the force required to fractured roots vertically after ultrasonic and Masserann removal of broken instruments. *Int Endod J*. 2012 May;45(5):429-34.
13. Shahabinejad H, Ghassemi A, Pishbin L, Shahravan A. Success of ultrasonic technique in removing fractured rotary nickel-titanium endodontic instruments from root canals and its effect on the required force for root fracture. *J Endod*. 2013 June;39(6):824-8.
14. Grossman LI. Guidelines for the prevention of fracture of root canal instruments. *Oral Surg Oral Med Oral Pathol*. 1969 Nov;28(5):746-52.
15. Spili P, Parashos P, Messer HH. The impact of instrument fractured on outcome of endodontic treatment. *J Endod*. 2005 Dec;31(12):845-50.