

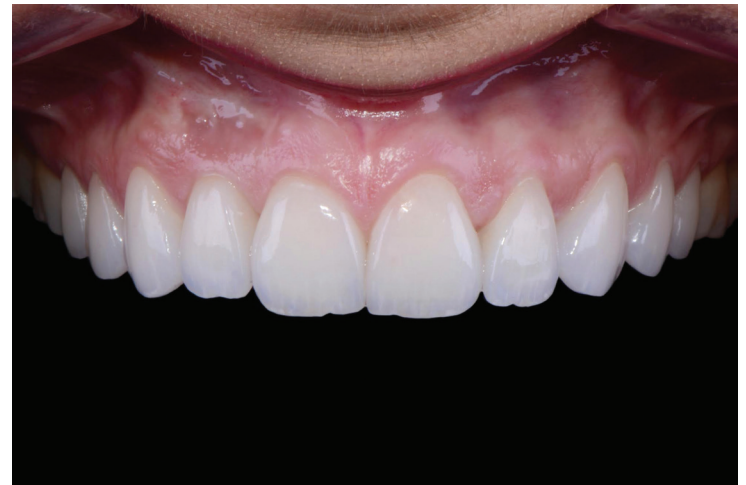
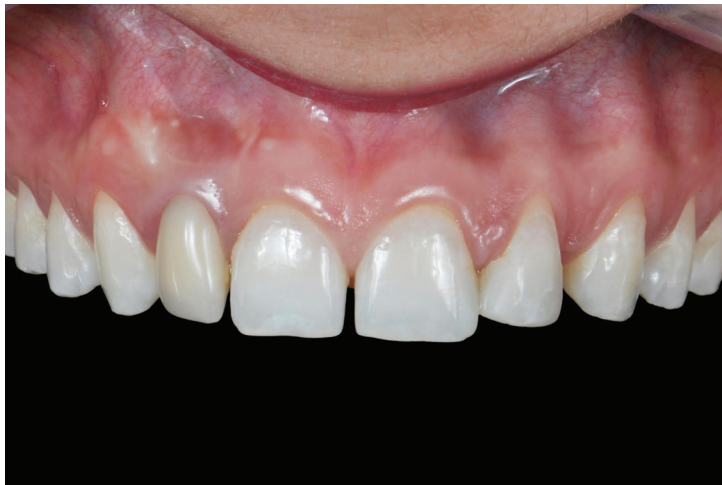Everything in life evolves, transits, changes; the internet has come to stay, technologies also, and the current restorative dentistry, in turn, goes through a transition that orthodontics and implantology have passed, and now esthetics is the next in line. When well indicated and performed, esthetic restorative treatments are amazing; but since there are not only flowers, the overtreatments are increasing improperly, and this ultimately harms the patients, who are often exposed in social media with not so real images. Talking with a great friend, dentist and photographer, Renato Ferreira, we discussed that the images photographed in JPEG are slightly adjusted by the camera itself; but when photographed in RAW, the file is indeed totally raw to be revealed. The purpose of this column is not saying what is right or wrong, judging or criticizing anyone's work. We are not worried about this. Rather, we want to show the reader and clinician, like us, the reality of the clinical cases performed, since in social media we only see photos that have been extremely adjusted and are not consistent with reality. We want to invite you to enter this journey where, in each issue, we will include "before and after" cases with a step by step description of treatment and without any image editing, as produced by the camera, to expose and show the "RAW AND NAKED" REALITY of dentistry. Some images are JPEG, others are RAW. This way, we want to remind you and observe that the most important are the concepts, techniques and basis for a good dentistry, emphasizing the quality of procedures.



RAFAEL DECURCIO

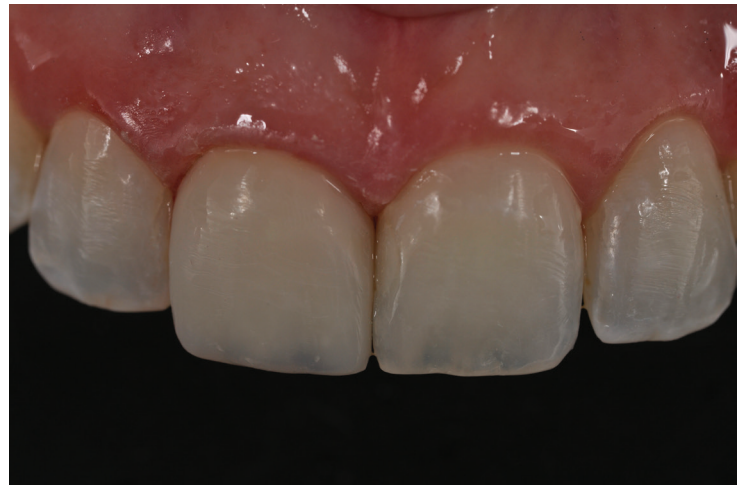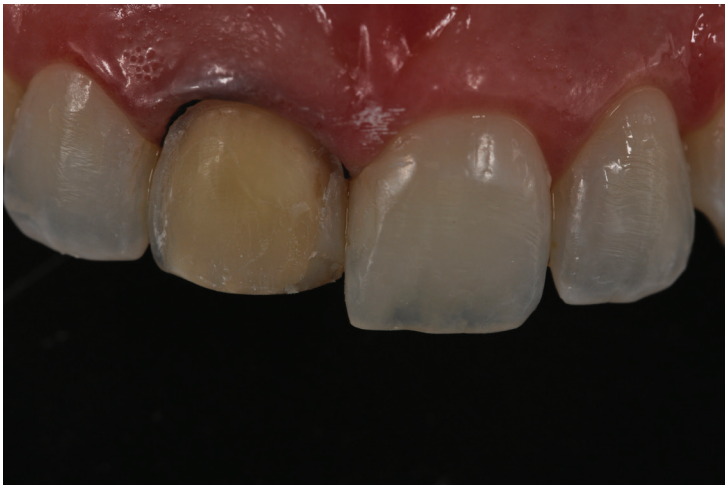Case: Patient aged 28 years, female, sought for care with the restorative dentistry team complaining of dissatisfaction with the esthetic conditions of her smile. After adequate anamnesis, clinical analysis and complementary imaging examinations, esthetic-functional rehabilitation planning could be performed. The patient received placement of a 3.0-mm Nobel Active endosseous implant (Nobel Biocare), associated with the regenerative technique of biomaterial and connective tissue grafting, and immediate provisionalization at the region of tooth #12, for replacement of a provisional adhesive fixed denture. In the same operative procedure, surgery was performed to increase maxillary clinical crowns, for adequacy of periodontal esthetic references, correcting the zeniths, contour shapes

and cervical lengths. After the healing period, the patient was submitted to in-home tooth whitening with Opalescence PF 10% (Ultradent), for color equalization of substrates and to increase their value, providing better conditions for conservative restorations. After color stabilization, the rehabilitation therapy was performed using ceramic contact lens and ceramic crowns on zirconia infrastructure placed on endosseous implant abutment. After a 6-year follow-up, the patient is satisfied with the result, and the clinical data reveal the stability and success of rehabilitation.



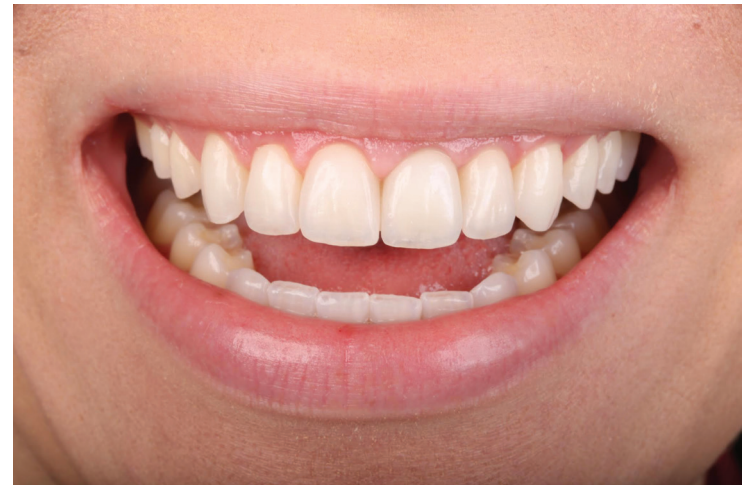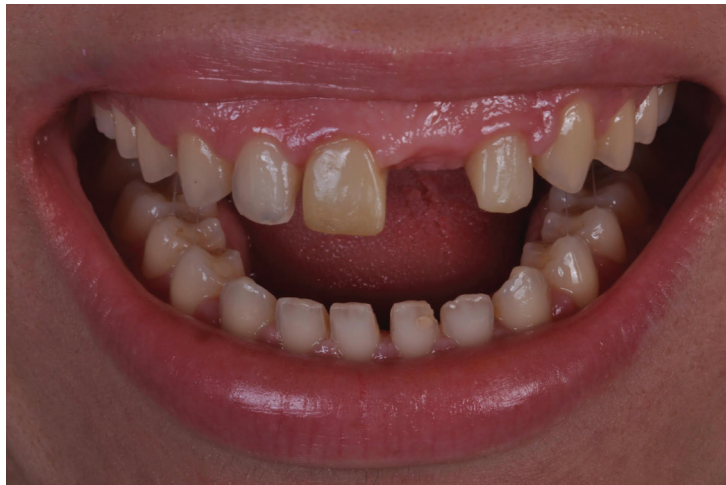THIAGO OTTOBONI

Case: Patient requiring restorative treatment of tooth #11 due to trauma, endodontic treatment and old composite resin veneer. We decided to change the old resin veneer by composite resin due to the cost. Diagnostic setup and preparation were carried out removing all the old resin, with better definition of the intra-sulcular margin, followed by hybridization and stratification to improve the substrate using dye (White ex: Express Direct Color or Estelite Color), then using a layer of dentin of the desired shade, to give shape and color morphology, achromatic enamel resins to achieve the opalescent effect, and a layer of chromatic enamel to finalize the tooth value.



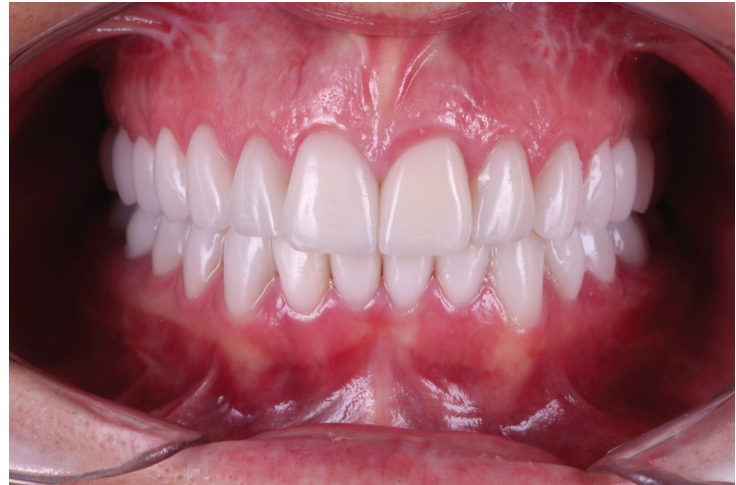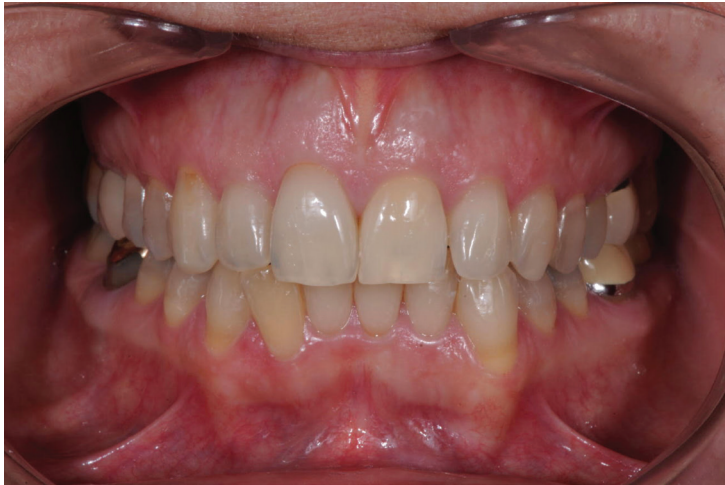Case performed by the team of **ATELIÊ ORAL** and **GUSTAVO GIORDANI**
Ceramists: **LEONARDO BOCABELLA** and **LAB PRECISION**

Case: After fixed orthodontic treatment with skeletal anchorage, we noticed ankylosis of tooth #23, which limited the refined finalization of pink esthetics. We chose to perform a clinical crown increase from tooth #11 to #15, plus implant with connective tissue graft on tooth #21 and root coverage on the ankylosed tooth #23, to level the gingival margin with the upper lip. We finished with ceramic restorations from tooth #15 to #25, taking the lower lip as reference for the smile curvature. Finally, ceramic laminates were used from teeth #33 to #43 to close the diastemas and improve the tooth shape.



Case performed by the team at **ATELIÊ ORAL, LAB PRECISION** and **LUIS CALICHIO**

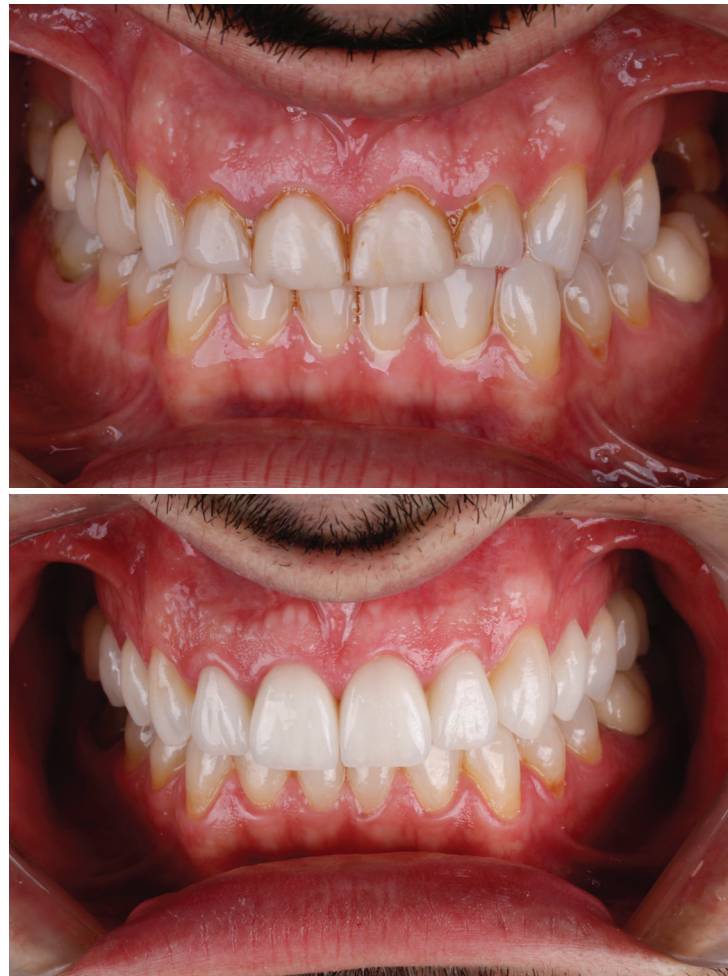Case: In complex cases, the correct timing of action of specialties is fundamental to assure the functional, biological and esthetic balance of treatment. In this case, fixed orthodontics provided the ideal conditions for oral rehabilitation with ceramic restorations.



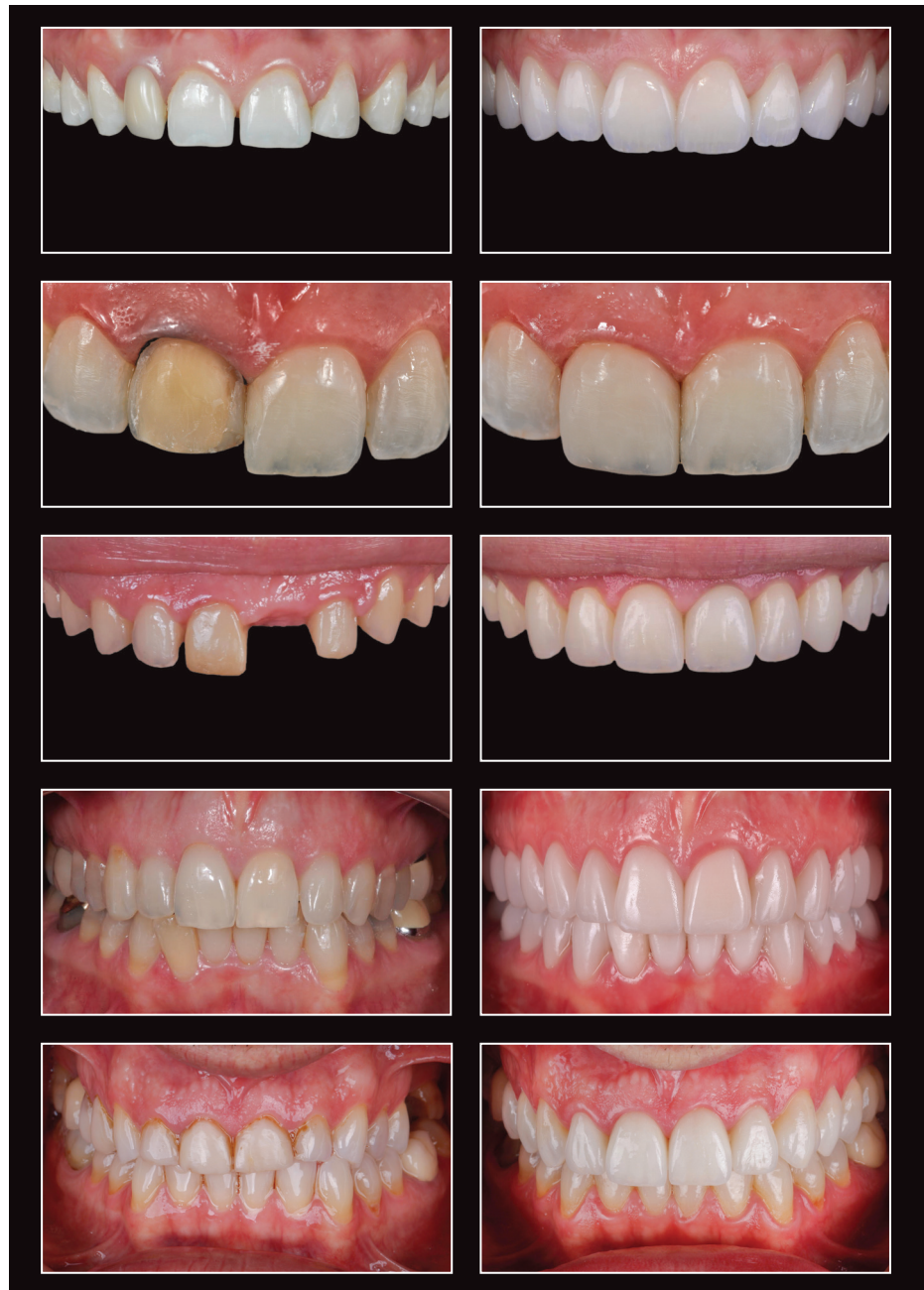**ANDRÉ CALEGARI | JULIANA DORNELLES |
ADRIANO SHAYDER**

Case: The patient who illustrates these images presented to the multidisciplinary team searching for a more appropriate esthetic solution for his case, within what was possible. An adult patient with masticatory dysfunction, whose chief complaint was the lack of esthetics of maxillary teeth and loss of a “posterior tooth”. Initial clinical and radiographic examination revealed the presence of extensive and poorly adapted composite resin restorations in teeth #15, 14, 12, 11, 21, 22, 24, ceramometal crown in tooth #25, absence of tooth #26 and fractured restoration on tooth #17. Photographs, imaging examinations and impressions were achieved for diagnostic setup. After receiving the waxing and walls from the laboratory, the mock-up of the new smile was performed, so that the work team approved the result, and especially the patient. The proposed treatment included implant placement at the region of tooth #26, restoration of tooth #27, removal of the crown of tooth #25 and preparations for laminated veneers in teeth #24 to #15. It was decided that rehabilitation of the mandibular arch would be performed in another stage. That said, surgery was performed for implant placement at the region of tooth #26, removal of crown of tooth #25, and preparations were performed for laminate veneers of the other teeth, guided by the mock-up. After gingival retraction, a double impression with programmed

reliefs was obtained using virtual addition silicone (Ivoclar Vivadent). Two casts (die and hard) were produced in the laboratory, and ceramics IPS E.max Press MT (Ivoclar Vivadent) was selected, with posterior stratification by the “cut back” technique of teeth #13 to #23. In the clinic, the teeth were fitted and cemented with Variolink LC resin cement (Ivoclar Vivadent) for the veneers, Variolink N (Ivoclar Vivadent) for the crown and implant-supported denture. The necessary occlusal adjustments were performed and, as usual, a bite plate was indicated for nighttime use.



Suggestion of color treatment, trimming, background filling and occlusal plane adjustment using Adobe® Photoshop and Lightroom softwares. Edition: Júnior Bianchi



THIAGO OTTOBONI

1. Instituto de Pós-graduação e Pesquisa em Odontologia (Balneário Camboriú/SC, Brazil).
2. Private practice (Blumenau/SC, Brazil).

DOI: <https://doi.org/10.14436/2447-911x.15.2.086-093.inc>